

CASE REPORT

Solar Retinopathy with Interesting Imaging Findings. A Case Report

OH KL¹, WONG HS¹, SAFINAZ MK¹, LAKANA K², HAZLITA MI¹

¹Department of Ophthalmology, Faculty of Medicine, Universiti Kebangsaan Malaysia Medical Centre, Jalan Yaacob Latif, Bandar Tun Razak, 56000 Cheras, Kuala Lumpur, Malaysia.

²Department of Ophthalmology, Hospital Kuala Lumpur, Jalan Pahang, 50586 Kuala Lumpur, Malaysia.

ABSTRAK

Solar retinopathi merupakan satu penyakit retina yang disebabkan oleh pandangan terhadap cahaya matahari. Diagnosis penyakit ini amat mencabar dan memerlukan sejarah kesihatan dan penyiasatan yang teliti. Laporan kes ini adalah berkenaan seorang pemetik buah-buahan yang berumur 55 tahun yang mengalami kehilangan penglihatan kekal di bahagian tengah medan penglihatan. Diagnosis solar retinopathi telah dibuat berdasarkan kepada sejarah yang diberi oleh pesakit berkenaan, bersama penyiasatan menggunakan pengimejan seperti optical coherence tomography (OCT), infra merah (IF) dan fundus autofluorescence (FAF) yang memainkan peranan penting dalam kes ini. Kesimpulannya, solar retinopathi adalah satu penyakit yang sukar untuk dipulihkan. Penyiasatan dengan cara pengimejan memainkan peranan yang penting untuk merangkul diagnosis yang betul. Justeru itu, pemakaian cermin mata hitam adalah disarankan untuk semua pesakit yang sering terdedah kepada cahaya matahari.

Kata kunci: fundus autofluorescence, inframerah, optical coherence tomography, cahaya matahari, solar retinopathi

ABSTRACT

Solar retinopathy is an injury of the retinal photoreceptors due to excessive exposure to the solar radiation. Diagnosis of the disease is challenging and requires combination of a detailed history and imaging modalities. This case report focuses on a 55-year-old fruit picker with an irreversible central scotoma of the right eye. A diagnosis of solar retinopathy was made based on history but mainly by several imaging modalities, such as optical coherence tomography (OCT), infrared (IF) imaging of the fundus and fundus autofluorescence (FAF). Electroretinogram (ERG)

Address for correspondence and reprint requests: Hazlita Mohd Isa, Department of Ophthalmology, Faculty of Medicine, Universiti Kebangsaan Malaysia Medical Centre, Jalan Yaacob Latif, Bandar Tun Razak, 56000 Cheras, Kuala Lumpur, Malaysia. Tel:+603-91455981 Fax: +603-91737836 E-mail: drhdm@yahoo.co.uk

showed flattened and reduced waves in both scotopic and photopic response. Fundus angiography (FA) revealed no obvious telangiectatic vessels. In conclusion, solar retinopathy is a disease where multimodal imaging may play an important role in the diagnosis. The condition may be irreversible thus advocating protective eyewear is mandatory in patients who are chronically exposed to the sun.

Keywords: fundus autofluorescence, infrared, optical coherence tomography, sun gazing, solar retinopathy

INTRODUCTION

Solar retinopathy is an insult of the retina photoreceptors which results from direct or indirect exposure to sun light. The damage is postulated to be due to the exposure to the visible blue light and the ultraviolet radiation (Schubert 2013). It is commonly associated with sun gazing, solar eclipse viewing, religious rituals or prolonged exposure to ophthalmic microscope light (Yannuzzi et al. 1987).

There are several imaging modalities that can be used to detect the changes in solar retinopathy. Spectral domain optical coherence tomography (SD-OCT) remains an important imaging tool in showing the damage of the photoreceptor layers (Chen et al. 2012). Our following case utilized the high definition, spectral domain optical coherence tomography (SD-OCT) from Spectralis (Heidelberg Engineering, USA) to depict the exact layers of the macula pathology in solar retinopathy. Besides that, we also picked up changes from the infrared (IF) and the fundus auto fluorescence (FAF) which corresponded to each other.

CASE REPORT

A 55-year-old fruit picker presented with right gradual reduction in vision

for the past 2 yrs. There were no other associated ocular symptoms such as pain, redness or swelling of the periorbital region. The patient denied any history of trauma or foreign body entry into the eye. His past medical and ocular histories were unremarkable. Due to his occupation however, he did admit that his job required him to constantly gaze up to the sky, while wrapping fruits in the farm where he had inevitably looked directly at the sun from time to time. He denied wearing any protective sunglasses at work.

Upon presentation, his visual acuity was 6/36 in his right eye and 6/9 in his left eye, with no relative afferent pupillary defect. Clinical examination revealed normal anterior segments bilaterally. On funduscopy however, the right fundus showed multiple deep hypopigmented lesions at the parafovea region with a mottled macula (Figure 1). The left fundus was normal.

RESULTS

SD-OCT showed generalised outer retina thinning of the right macula with a fairly intact external limiting membrane (ELM). There was presence of a sudden disruption of inner and

outer segments of photoreceptors at the fovea with cavitations. Segmentations of retinal pigment epithelium (RPE) interdigitations were noted. Otherwise, the RPE/Bruch's membrane complex was intact (Figure 2).

We proceeded by performing IR and FAF tests of the right eye. IR revealed multiple hypo-reflective areas at the macula region (Figure 3). FAF showed a rim of hypoautofluorescence surrounding the fovea with intervening area of hyperautofluorescence (Figure

4). FA was performed and did not show any obvious telangectatic vessels (Figure 5). ERG revealed flattened and reduced waves in both scotopic and photopic response. The OCT, IR, FAF, FA and ERG of the left eye appeared normal. In view of his exposure to sunlight and findings from the multimodal imaging, a diagnosis of right eye solar retinopathy was made.

This patient was followed up for duration of two years and his right vision had no improvement. Clinically,

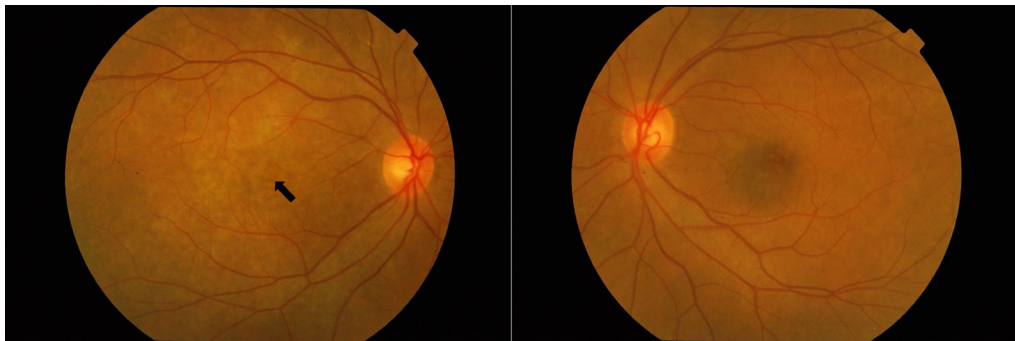


Figure 1: Color fundus photographs of right and left eyes. Right fundus showed multiple deep hypopigmented lesions with a dull macula. Left fundus was normal.

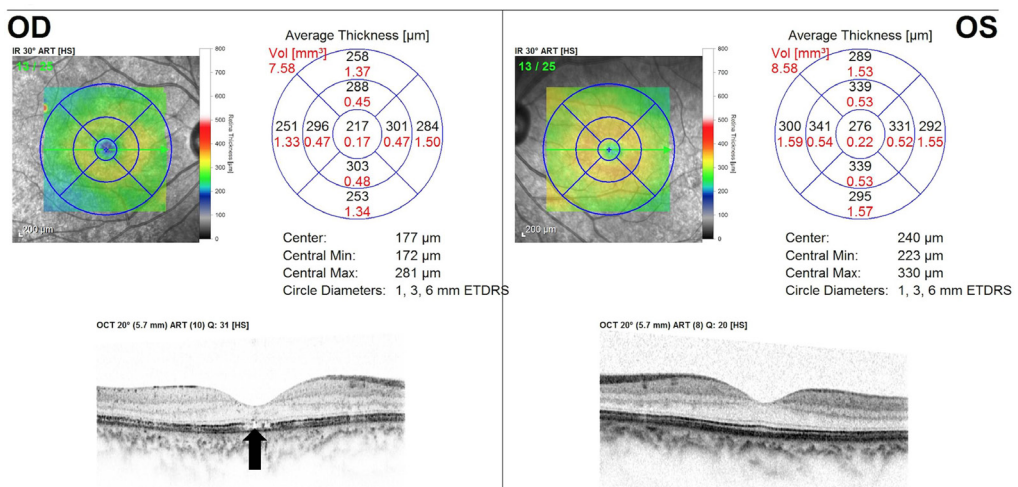


Figure 2: SD-OCT of right and left eyes. OCT of right eye showed generalised thinning, disruption of photoreceptors with cavitations and RPE interdigitations. OCT of left eye was normal.

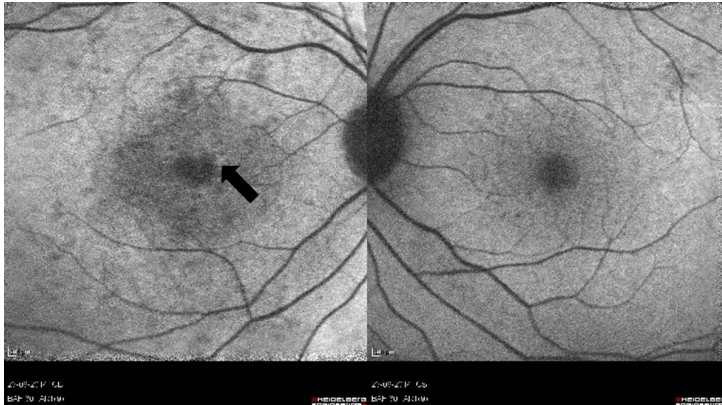


Figure 3: IR of right and left eyes. IR of right eye showed multiple hyper-reflective areas at the macula region. Left eye was normal.

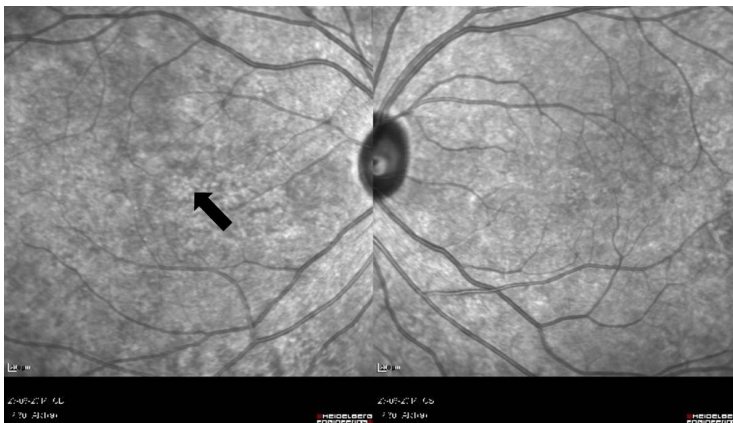

Figure 4: FAF of right and left eyes. FAF of right eye showed a rim of hypoautofluorescence surrounding the fovea with intervening area of hyperautofluorescence. Left eye was normal.

his fovea remained mottled and a repeat OCT showed similar findings. Due to his chronicity of sun exposure and the ocular findings, we counseled him that his right vision may not improve in future and advised him to use protective eyewear to protect his left eye.

DISCUSSION

Solar retinopathy is a disease of the outer retina layer. Although the disease

commonly affects both eyes, there are previous reports of unilateral solar retinopathy similar to our patient (Sheth et al. 2013; Dhir et al. 1981). It is postulated that unilateral cases are attributed to the uneven reflex blinking of the eyes and one eye being the more dominant than the other, hence the dominant eye is affected more.

Several modalities can be used to detect the retina changes in this condition. Bechmann et al. (2000) first described the changes associated

with solar retinopathy using time domain OCT where they found a hyper-reflective area affecting all layers at the fovea. Other changes that have been documented by various literature reviews include abnormal reflectivity at the outer foveal retina with or without retina thickening, disruption of the inner and outer segments of photoreceptors and hyporeflexive area of the underlying retinal pigment epithelium (Khatib et al. 2014).

In our case, the patient's fundus showed a mottled macula which indicates the chronicity of the disease. OCT showed generalized thinning of the outer retinal layers with preservation of the inner retinal layers thickness. This is in keeping with the fundamental understanding that solar retinopathy manifests as an outer retinal pathology. Interestingly in our case, the ELM layer was preserved. Another interesting feature seen in the OCT of this case is the presence of cavitations at the photoreceptor layers, similar with the cavitation at the inner retinal layer seen in macular telangiectasia type 2 (Charbel Issa et al. 2013). We postulate that this is most likely due to the loss of the photoreceptor tissues.

Our patient also demonstrated a hyperreflective area on IR which corresponded with the rim of parafovea hypoautofluorescence area seen on FAF. This finding was well depicted from the colour fundus photograph which revealed hypopigmented lesions. These changes however were not previously reported in other cases associated with solar retinopathy. Based on these

adjunct multimodality images, we believe that solar retinopathy is not only a disease of the outer retinal layers but could also involve the retinal pigment epithelium (RPE) and choroidal areas as evidenced by the changes in AF and in IR images respectively.

CONCLUSION

Solar retinopathy remains an occupational hazard to people who are chronically exposed to sun. Careful history and clinical examination are pivotal in obtaining the diagnosis. The use of multimodal imaging is useful in depicting the changes of the retinal layers and to further assist us in understanding the pathology better.

REFERENCES

- Bechmann, M., Ehrh, O., Thiel, M.J., Kristin, N., Ulbig, M.W., Kampik, A. 2000. Optical coherence tomography findings in early solar retinopathy. *Br J Ophthalmol* **84**(5): 547-8.
- Charbel Issa, P., Gillies, M.C., Chew, E.Y., Bird, A.C., Heeren, T.F., Peto, T., Holz, F.G., Scholl, H.P. 2013. Macular telangiectasia type 2. *Prog Retin Eye Res* **34**: 49-77.
- Chen, K.C., Jung, J.J., Aizman, A. 2012. High definition spectral domain optical coherence tomography findings in three patients with solar retinopathy and review of the literature. *Open Ophthalmol J* **6**: 29-35.
- Dhir, S.P., Gupta, A., Jain, I.S. 1981. Eclipse retinopathy. *Br J Ophthalmol* **65**(1): 42-5.
- Khatib, N., Knyazer, B., Lifshitz, T., Levy, J. 2014. Acute eclipse retinopathy: a small case series. *J Optom* **7**(4): 225-8.
- Schubert, H.D. 2013. Retina and Vitreous. Basic and Clinical Science Course, Section 12. American Academy of Ophthalmology.
- Sheth, J., Vidhya, N., Sharma, A. 2013. Spectral-domain optical coherence tomography findings in chronic solar retinopathy. *Oman J Ophthalmol* **6**(3): 208-209.
- Yannuzzi, L.A., Fisher, Y.L., Krueger, A., Slakter, J. 1987. Solar retinopathy : a photobiological and geophysical analysis. *Trans Am Ophthalmol Soc* **85**: 120-158.