

Morphologic Evaluations of Hypoglossal Canal using Cone Beam Computed Tomography

(Penilaian Morfologi Saluran Hipoglossus menggunakan Tomografi Pemancaran Kon Berkomputer)

ŞUAYIP BURAK DUMAN*, MEHMET SEYREK, YASİN YAŞA, İSMAİL GÜMÜŞSOY, NUMAN DEDEOĞLU & İBRAHİM ŞEVKİ BAYRAKDAR

ABSTRACT

Hypoglossal canal (HC) which begins from very slightly above the inner part of the anterolateral portion of the foramen magnum and is located above the occipital condyle of the occipital bone. The aim of this study is to examine HC morphology and variations using cone beam computed tomography (CBCT). The morphology and types of HC were investigated with 303 CBCT images (606 side). Type 1 variation in 606 HC examined becomes the most commonly observed type (57.3%) while type 5 variation was the least common type of variation (0.8%). Type 1 HC was statistically higher in males ($p=0.004$). Because of HC, which is an anthropologically important point and enters the field of images in CBCT scan, it is recommended that dental radiologists should be aware of their variations and be wary of the pathologies that may occur in this region.

Keywords: CBCT; foramen magnum; hypoglossal canal; occipital condyle

ABSTRAK

Saluran hipoglossus (HC) yang bermula di bahagian atas sedikit pada bahagian dalaman anterosisi foramen magnum dan terletak di atas kondil oksipital tulang oksipital. Tujuan kajian ini adalah untuk mengkaji morfologi dan variasi HC menggunakan tomografi pemancar kon berkomputer (CBCT). Morfologi dan jenis HC dikaji dengan 303 imej CBCT (sisi 606). Variasi jenis 1 pada 606 HC yang disemak menjadi jenis yang paling sering diperhatikan (57.3%) sementara variasi jenis 5 adalah jenis variasi yang paling jarang (0.8%). HC Jenis 1 secara statistik lebih tinggi pada lelaki ($p = 0.004$). Oleh kerana HC, yang merupakan titik penting antropologi dan memasuki bidang pengimejan dalam imbasan CBCT, disarankan agar ahli radiologi gigi harus mengetahui variasinya dan berhati-hati dengan patologi yang mungkin berlaku pada bahagian ini.

Kata kunci: CBCT; foramen magnum; kondil oksipital; saluran hipoglossus

INTRODUCTION

The hypoglossal canal (HC) begins from very slightly above the inner part of the anterolateral portion of the foramen magnum and is located above the occipital condyle of the occipital bone (Williams et al. 1989). The HC is located in the occipital bone at the junction of the anterior third and posterior two thirds of the occipital condyle. It is one of the immutable characteristics of the human skull (DeGusta et al. 1999).

The hypoglossal nerve is the only motor support of the tongue muscles, the upward branch of the pharyngeal

artery (B), the meningeal branch of the hypoglossal nerve providing sensory innervation of the posterior cranial fossa, and the venous plexus connecting the inferior petrosal plexus, the anterior condylar vein and the paravertebral venous plexus pass through this canal (Standing 2005). The venous plexus is thought to be of great importance as it forms the main source of venous drainage along the postsellar cranial cavity (Lang & Hornung 1993).

Variations in the anatomy of the HC may be critical for surgeons and radiologists. Although rarely observed, hypoglossal schwannomas (the primary neoplasm of HC),

vascular anomalies such as enlarged emissary veins and a persistent primitive hypoglossal artery may pose a risk for surgical procedures (Myatt et al. 1998). In the case of surgical intervention in any lesion containing the HC, the type and size of the tumour, age, and symptoms should be considered, along with the detailed anatomy of this foramen, as the cranial foramen can show significant racial and regional differences (Ari et al. 2005).

The size asymmetry of the HC and the bony bridge are major anatomical variations. Although numerous studies have been conducted using image analysis to evaluate these variations, the majority of studies have been conducted on a small number of skull samples. Such morphological studies generally provide important guidance in assessing deviations from normal anatomical changes and in maintaining vital structures during surgical intervention.

Innovations in 3D imaging methods have greatly improved the display of craniofacial structures (Mah 2003). Frequent use of cone beam computed tomography (CBCT) in dentistry has also increased in recent years. Compared to CT, its low radiation dose, relatively short imaging time and high hard tissue resolution make it an alternative method of imaging in the head and neck region (Geist et al. 2014).

Many studies in the literature evaluating HC variations have been conducted on skulls, while only a few studies have been conducted on CT (Ari et al. 2005; Lang & Hornung 1993; Myatt et al. 1998). The aim of this study was to examine HC morphology and variations using CBCT.

MATERIALS AND METHODS

STUDY POPULATION

We performed a retrospective study using CBCT images from 303 patients (606 double-sided) who were admitted to the oral and maxillofacial radiology service at Inonu

University's Faculty of Dentistry. If the desired structure was not involved in the field of view (FOV) or the images were not of the desired quality, the patients were not included in the study. An ethics committee report was obtained for this retrospective study from the Scientific Research and Publication Ethics Committee of Inonu University (2019/6-24).

CBCT IMAGE ACQUISITION AND ANALYSIS

For CBCT images, a NewTom 5G (QR, VERONA, ITALY) device with 110kVp and maximum 20 mA as standards, 0.125 mm voxel size and 0.25 mm axial and sagittal sections were used. Three-dimensional images were created using New Tom (NNT) software according to the manufacturer's instructions. Patients were in a supine position, and the Frankfort horizontal plane was perpendicular to the table, with the head within the circular gantry housing of the X-ray tube-detector system. The duration of imaging was 18 seconds. Images with an adjustable FOV of 18 × 16 or 15 × 12 cm were used.

Hauser et al. (1985) classified HC variations into five different types using bone samples of HC anatomy (Hauser & De Stefano 1985). Type 1. No sign of cleavage. A simple canal; Type 2. Cleavage present. An osseous spine at either the outer or inner orifice of the canal; Type 3. Two or more osseous spines anywhere along the walls of the canal; Type 4. Complete osseous hypoglossal bridging in the internal or external part of the canal; and Type 5. Complete osseous hypoglossal bridging along the whole canal.

The HC is defined as an occipital bone canal extending from the posterior cranial fossa to the nasopharyngeal carotid space. After the images were reconstructed, they were examined along the course of the HC in the sagittal plane, and variations were recorded (Figure 1). The variations recorded in the sagittal plane were re-examined and confirmed in the axial plan. After reconstruction, variations were reevaluated through 3D images (Figure 2).

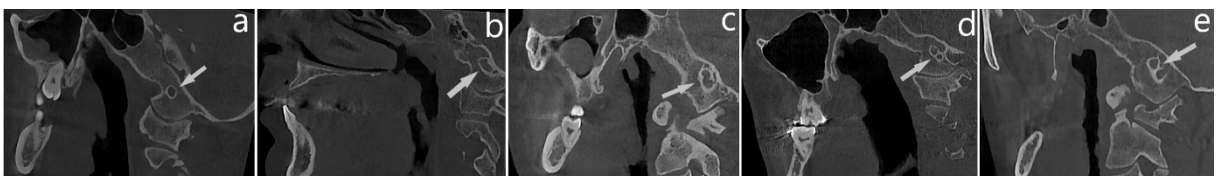


FIGURE 1. Variations of the HC in the sagittal plane




FIGURE 2. 3D images of the reevaluated variations

STATISTICAL ANALYSIS

SPSS v20.0 for Windows (SPSS Inc., Chicago, IL, USA) was used for all statistical analyses. Kolmogorov-Smirnov statistics were used for the normality test, and statistical significance was accepted at $P < 0.05$.

CBCT images were scanned by an experienced oral radiologist (S.B.D.) and 25% of them were re-evaluated by the same person 2 weeks later. The intraclass correlation coefficient (ICC) was used to determine intrarater reliability. ICC values were 0.969 for the classifications of the right side and 0.956 for the classifications of the left side. In the classification of HC types by gender, the Chi-Square and Fisher's Exact test were applied.

RESULTS

A total of 606 HC was examined in 303 patients (166 females, 137 males). Type 1 variation was the most common type (29.8% right, 27.5% left), and Type 5 (0.65% right, 0.15% left) was the least common type of variation (Table 1). The incidence of double HC (Type 4 + Type 5) was 20.5% on the right side and 19.1% on the left side, while bilateral HC was seen in 6% (Table 2). Looking at the differences in HC types based on gender, it was found that Type 1 HC was significantly more frequent in males than in females ($p=0.004$). There were no significant differences in other types by gender (Table 3). The distribution of HC types by age is shown in Table 3.

TABLE 1. Distribution of hypoglossal canal variations according to gender and side

	Female (n=166)		Male (n=137)		Total (n=303)	
	Right Side	Left Side	Right Side	Left Side	Right Side	Left Side
Simple canal	93 (28%)	82 (24.6%)	88 (32.1%)	85 (31%)	181 (29.8%)	167 (27.5%)
An osseous spine at either the outer or inner orifice of the canal	26 (7.8%)	36 (10.8%)	19 (6.9%)	17 (6.2%)	45 (7.4%)	53 (8.7%)
Two or more osseous spines anywhere along the walls of the canal	12 (3.6%)	15 (4.5%)	3 (1.1%)	10 (3.6%)	15 (2.5%)	25 (4.1%)
Complete osseous hypoglossal bridging in the internal or external part of the canal	34 (10.2%)	33 (9.9%)	24 (8.7%)	24 (8.7%)	58 (9.5%)	57 (9.4%)
Complete osseous hypoglossal bridging along the whole canal	1 (0.3%)	0	3 (1.1%)	1 (0.35%)	4 (0.65%)	1 (0.15%)

TABLE 2. Prevalence of double hypoglossal canal (Type 4+5)

	Female (n=166)	Male (n=137)	Total (n=303)
Right side	35 (21.1%)	27 (19.7%)	62 (20.5%)
Left side	33 (19.9%)	25 (18.2%)	58 (19.1%)
Bilateral	11 (6.8%)	7 (5.1%)	18 (6%)

TABLE 3. Comparison of HC types by gender

	Male		Female		Chi square test
	n	%	n	%	P value
Type 1	173	63.1	175	52.6	0,004*
Type 2	36	13.1	62	18.6	0,065
Type 3	13	4.7	27	8.1	0,095
Type 4	48	17.4	67	20.1	0,405
Type 5	4	1.45	1	0.3	0,181

DISCUSSION

The HC lies slightly above the anterolateral border of the foramen magnum, between the occipital condyle and jugular tubercle, and contains a meningeal branch of the ascending pharyngeal artery and an emissary vein from the basilar plexus (Williams et al. 1989). It basically provides motor innervation to the intrinsic tongue musculature. Numerous studies have been conducted to describe variations of the canal; however, no studies have investigated variations of the HC using CBCT. From this perspective, our study is the first to investigate HC variations with CBCT.

Hypoglossal canal variations, especially bridging and duplication patterns, are a topic of interest and frequently studied by researchers. Jones and Wen (1934) were the first researcher to suggest that these variations may be a special anthropological variety for different races. Kay et al. (1998) suggested that there may be a relationship between HC size and speech abilities, based on the conclusion that the HC sizes of living things that are less advanced than humans are smaller. In a later

study, however, this thesis was opposed by DeGusta et al. (1999). The effect of genetic factors on HC variations has been proven in both animal (Cheverud & Buikstra 1978; Self & Leamy 1978) and human studies (Sjøvold 1984).

In literature, hypoglossal canal variations studies on the Anatolian population are heavily anthropological studies on cadavers of ancient civilizations. Ari et al. (2005) used Hauser and De Stefano's (1985) method in their anthropological study of 25 Byzantine skulls and examined the five types of HC. While mostly Types 1 and 2 variations were observed, they found other types at a rate of between 10 and 2%. Our study was conducted with a much larger number of samples (303) than their study. Types 1, 2, 3, 4, and 5 were found to occur in 57.3, 16.1, 6.6, 18.9, and 0.8% of cases, respectively. In a study conducted in Greece, which lies adjacent to the Anatolian civilization, the HC variations in 116 skulls were as follows: Type 1 59, Type 2 18, Type 3 0.86, Type 4 19, and Type 5 1.72% (Paraskevas et al. 2009).

A group of researchers examined the prevalence of double HC (Types 4, 5) in the Japanese population under

CT guidance. According to their research, 2.2 of the 16.9% of double HC was found to be bilateral. In addition, double HC was found to be significantly more frequent in males and on the left than in females and on the right (Kanda et al. 2015). In our study, double HC was bilateral in 6% of cases. Kondo et al. (2007) have suggested that in clinical situations such as dural AVF it is important to assess HC bridging to help figure out various pathological processes. The emissary vein and venous plexus, which play an important role in the venous circulation, insert into the HC. Bony changes in the HC with dural AVF were reported in this region.

Okamura et al. (2016) mentioned that they successfully treated a case of dural arteriovenous fistula of the anterior condylar confluence (ACC-DAVF) under CBCT guidance and that CBCT was successful in HC imaging. Similarly, Kadooka et al. (2018) investigated the efficacy of CBCT in the treatment of dural arteriovenous fistula in cavernous sinus and concluded that CBCT can provide the best definition of feeders and their course through the bony structures and distinction from the cavernous sinus. Although tumoral lesions of the HC region are not very common, a good understanding of the anatomy of the region before possible surgical intervention for the lesions developing in this region plays a vital role in the treatment of lesions (Hadley & Shelton 2004). Hypoglossal schwannoma, which occurs intracranially and extends from the HC to the extracranial cavities, is the most common lesion in this region (Tatagiba et al. 2006). Following this, glomus jugulare tumours, metastases, myelomas, and rarely meningiomas are also observed (Voyvodic et al. 1995). Although several approaches have been proposed for the surgical planning of such lesions, the anatomy and morphology of the respective region must be examined closely by surgeons and radiologists to avoid hypoglossal nerve damage before planning surgical operations (Muthukumar et al. 2005).

Due to rapid advances in technology, the use of intraoperative navigation is increasing and is expected to become widespread in the future. CBCT, which is frequently used in dentistry, has also started to take its place in medicine with the increased use of intraoperative navigation (Steenbergen et al. 2019). Intraoperative CBCT navigation allows real-time imaging of the positions of surgical instruments using high-resolution 3D images with a low radiation dose. Another advantage of CBCT is that it does not take up much space in operating rooms and allows practical use. CBCT thus provides the advantage of intraoperative navigation for the preservation of vital structures and facilitates the retrieval of control scans in

the validation of surgical procedures (Steenbergen et al. 2019; Takahata et al. 2018).

There were some limitations in our study including the limited number of subjects and the age range of the study group. Further studies should include a larger population with a wider age range.

CONCLUSION

As the HC, which is an anthropologically important point, enters the field of images in CBCT scans, it is recommended that dental radiologists should be aware of its variations and be wary of the pathologies that may occur in this region. The results of this study will provide reference information for physicians planning surgical procedures and forensic scientists.

ACKNOWLEDGEMENTS

The authors declare that they have no conflict of interest. This study received no funding. This article does not contain any studies with living human participants or animals. Institutional approval was given. For this type of study, formal consent is not required.

REFERENCES

- Ari, I., Kurt, M., Oygucu, I. & Sendemir, E. 2005. Variations in the bridging trait of the hypoglossal canal in 13th century Byzantine skulls. *International Journal of Osteoarchaeology* 15(2): 140-145.
- Cheverud, J.M. & Buikstra, J.E. 1978. A study of intragroup biological change induced by social group fission in *Macaca mulatta* using discrete cranial traits. *American Journal of Physical Anthropology* 48(1): 41-45.
- DeGusta, D., Gilbert, W.H. & Turner, S.P. 1999. Hypoglossal canal size and hominid speech. In *Proceedings of the National Academy of Sciences*. United States National Academy of Sciences. pp. 1800-1804.
- Geist, J.R., Geist, S.R.Y. & Lin, L. 2014. A cone beam CT investigation of ponticulus posticus and lateralis in children and adolescents. *Dentomaxillofacial Radiology* 43(5): 1-7.
- Hadley, K.S. & Shelton, C. 2004. Infratemporal fossa approach to the hypoglossal canal: Practical landmarks for elusive anatomy. *The Laryngoscope* 114(9): 1648-1651.
- Hauser, G. & De Stefano, G. 1985. Variations in form of the hypoglossal canal. *American Journal of Physical Anthropology* 67(1): 7-11.
- Jones, F.W. & Wen, I.C. 1934. The development of the external ear. *Journal of Anatomy* 68(4): 525-533.
- Kadooka, K., Tanaka, M., Sakata, Y., Ideguchi, M., Inaba, M. & Hadeishi, H. 2018. Efficacy of cone beam computed tomography in treating cavernous sinus dural arteriovenous fistula. *World Neurosurgery* 109: 328-332.

- Kanda, T., Kiritoshi, T., Osawa, M., Toyoda, K., Oba, H., Kotoku, J., Kitajima, K. & Furui, S. 2015. The incidence of double hypoglossal canal in Japanese: Evaluation with multislice computed tomography. *PLoS ONE* 10(2): 1-8.
- Kay, R.F., Cartmill, M. & Balow, M. 1998. The hypoglossal canal and the origin of human vocal behavior. *Proceedings of the National Academy of Sciences* 95(9): 5417-5419.
- Kondo, Y., Kiyose, H., Hori, Y., Kashiwagi, J., Sagara, Y. & Tanoue, S. 2007. Anterior condylar vein dural AVF with intraosseous vascular nidus in the hypoglossal canal: A case report. *Journal of Neuroendovascular Therapy* 1: 31-35.
- Lang, J. & Hornung, G. 1993. The hypoglossal channel and its contents in the posterolateral access to the petroclival area. *Neurochirurgia* 36(3): 75-80.
- Mah, J. 2003. *3-Dimensional Visualization of Impacted Maxillary Cuspids*. <http://www.aadmrt.com/article-1---2003.html>. Accessed on 15 September 2019.
- Muthukumar, N., Swaminathan, R., Venkatesh, G. & Bhanumathy, S. 2005. A morphometric analysis of the foramen magnum region as it relates to the transcondylar approach. *Acta Neurochirurgica* 147(8): 889-895.
- Myatt, H., Holland, N. & Cheesman, A. 1998. A skull base extradural hypoglossal neurilemmoma resected via an extended posterolateral approach. *The Journal of Laryngology & Otology* 112(11): 1052-1057.
- Okamura, A., Nakaoka, M., Ohbayashi, N., Yahara, K. & Nabika, S. 2016. Intraoperative cone-beam computed tomography contributes to avoiding hypoglossal nerve palsy during transvenous embolization for dural arteriovenous fistula of the anterior condylar confluence. *Interventional Neuroradiology* 22(5): 584-589.
- Paraskevas, G.K., Tsitsopoulos, P.P., Papaziogas, B., Kitsoulis, P., Spanidou, S. & Tsitsopoulos, P. 2009. Osseous variations of the hypoglossal canal area. *Medical Science Monitor* 15(3): 75-83.
- Self, S.G. & Leamy, L. 1978. Heritability of quasi-continuous skeletal traits in a randombred population of house mice. *Genetics* 88(1): 109-120.
- Sjøvold, T. 1984. A report on the heritability of some cranial measurements and non-metric traits. In *Multivariate Statistical Methods in Physical Anthropology*, edited by Van Vark G.N. & Howells, W.W. Dordrecht: Springer. pp. 223-246.
- Standring, S. 2005. *Gray's Anatomy: The Anatomical Basis of Clinical Practice*. 39th ed. New York: Elsevier Churchill Livingstone.
- Steenbergen, T.R.V., Geest, I.C.M.V.D., Janssen, D., Rovers, M.M. & Fütterer, J.J. 2019. Feasibility study of intraoperative cone-beam CT navigation for benign bone tumour surgery. *The International Journal of Medical Robotics and Computer Assisted Surgery* 15(3): 1-8.
- Takahata, M., Yamada, K., Akira, I., Endo, T., Sudo, H., Yokoyama, H. & Iwasaki, N. 2018. A novel technique of cervical pedicle screw placement with a pilot screw under the guidance of intraoperative 3D imaging from C-arm cone-beam CT without navigation for safe and accurate insertion. *European Spine Journal* 27(11): 2754-2762.
- Tatagiba, M., Koerbel, A. & Roser, F. 2006. The midline suboccipital subtonsillar approach to the hypoglossal canal: Surgical anatomy and clinical application. *Acta Neurochirurgica* 148(9): 965-969.
- Voyvodic, F., Whyte, A. & Slavotinek, J. 1995. The hypoglossal canal: Normal MR enhancement pattern. *American Journal of Neuroradiology* 16(8): 1707-1710.
- Williams, P., Warwick, R., Dyson, M. & Bannister, L. 1989. The individual cranial bones: Occipital bone. In *Gray's Anatomy: The Anatomical Basis of Clinical Practice*, edited by Standring, S. London: Elsevier Churchill Livingstone. pp. 371-373.
- Şuayip Burak Duman* & Numan Dedeoğlu
Department of Oral and Maxillofacial Radiology
Faculty of Dentistry
Inonu University Malatya
Turkey
- Mehmet Seyrek
Department of Ortodontics
Faculty of Dentistry
Fırat University, Elazığ
Turkey
- Yasin Yaşa
Department of Dentomaxillofacial Radiology
Faculty of Dentistry
Ordu University, Ordu
Turkey
- İsmail Gümüşsoy
Department of Dentomaxillofacial Radiology
Faculty of Dentistry
Sakarya University, Sakarya
Turkey
- İbrahim Şevki Bayrakdar
Department of Dentomaxillofacial Radiology
Faculty of Dentistry
Eskişehir Osmangazi University, Eskişehir
Turkey

*Corresponding author; email: suayipburakduman@gmail.com

Received: 29 October 2019

Accepted: 6 October 2020