

Retropharyngeal Abscess: A Seven-Year Review - Clinical Presentation, Diagnosis and Management

Abdul Fattah AW¹, Marina MB¹, Mazita A¹, Mohd Razif MY¹, Primuharsa Putra SHA²

¹ Department of Orthorhinolaryngology, Faculty of Medicine, Universiti Kebangsaan Malaysia, Kuala Lumpur

² Orthorhinolaryngology Consultant Clinic, Seremban Specialist Hospital, Negeri Sembilan

ABSTRAK

Ini adalah satu kajian retrospektif dengan merujuk kepada rekod-rekod pembedahan dari tahun 2000 hingga 2007. Rekod- rekod pembedahan tersebut diperolehi daripada dua buah pusat rujukan Otorinolaringologi (ORL) Malaysia. Kajian ini bertujuan untuk menilai struktur demografi, presentasi klinikal, dan rawatan bagi pesakit-pesakit yang mengalami jangkitan abses retrofaring. Terdapat lapan orang pesakit dalam kajian ini, lima perempuan dan tiga lelaki dengan median umur semasa mendapat rawatan iaitu 47 tahun. Faktor ko-mobiditi di dalam kajian ini adalah diabetis melitus, di mana empat orang pesakit menghidap diabetis. Tiga pesakit tertelan tulang ikan. Presentasi yang paling sering dialami oleh pesakit adalah sakit ketika menelan atau kesukaran untuk menelan. Walaubagaimanapun, tiada pesakit yang mengalami demam. Kesemua pesakit dirawat dengan antibiotik intravena dan pembedahan. Empat pesakit menjalani pembedahan mengeluarkan abses melalui rongga mulut, tiga pesakit menjalani pembedahan mengeluarkan abses melalui tepi leher dan abses pecah secara spontan terjadi kepada seorang pesakit. Kesemua pesakit sembuh dari jangkitan tersebut kecuali seorang sahaja yang meninggal dunia disebabkan septisemia.

Kata kunci: Abses retrofaring, rawatan transoral, sakit menelan, sukar menelan

ABSTRACT

This was a retrospective study of operative records between 2000 – 2007 from two ear, nose and throat (ENT) referral centers in Malaysia to review demographic patterns, clinical presentations and management of retropharyngeal abscess (RPA). Our case series comprised of eight patients with five females and three males with a median age at presentation of 47 years. Comorbid factor in this series was diabetes mellitus, with four patients having diabetes. There were three cases of fish bone ingestion. The commonest presentation was dysphagia or odynophagia. None of them had fever. All patients were treated with broad spectrum intravenous antibiotics (IV) and drainage was performed for the abscess. Four patients underwent transoral drainage with three having the cervical approach and one having spontaneous rupture.

Address for correspondence and reprint requests: Dr. Marina Bt Mat Baki, Department of Otorhinolaryngology, Faculty of Medicine, Universiti Kebangsaan Malaysia, Jalan Yaacob Latif, Bandar Tun Razak, 56000 Cheras, Kuala Lumpur. Fax: 603-91737840. Email: marinadrent@gmail.com

All patients recovered well from the infection and only one patient passed away due to septicaemia. In conclusion, patients with retropharyngeal abscess may present with vague symptoms of sore throat, odynophagia without fever due to partial antibiotics treatment. A correct diagnosis should be made so that adequate treatment can be given to prevent mortality.

Key words: Retropharyngeal abscess, transoral drainage, dysphagia, odynophagia

INTRODUCTION

The incidence of retropharyngeal abscess (RPA) is rare with the advent and wide usage of potent antibiotics. On the other hand, the diagnosis could be difficult due to its masked clinical symptoms (Ameh 1999, Philpott et al. 2004). Retropharyngeal abscess is common in children, with peak incidence at the age of three to five years old (Philpott et al. 2004, Kamath et al. 2007). Suppuration of retropharyngeal lymph nodes secondary to upper respiratory infection is the main cause in paediatric population (Kamath et al. 2007). In adults, it usually follows foreign body ingestion, trauma and in a rare occasion due to tuberculous infection of the cervical spine (Kamath et al. 2007, Goldenberg et al. 1997). Pak et al. (1999) have reported retropharyngeal abscess as a rare presentation in two patients with nasopharyngeal carcinoma.

Retropharyngeal abscess is a potentially serious infection due to its complications which involves upper airway obstruction, internal jugular vein thrombosis, mediastinitis, pericarditis, empyema, and carotid blow out (Pak et al. 1999, Craig & Schunk 2003, Chao et al. 1999, Siou & Yates 2000). Current mortality rate due to these complications accounts to 25% (Furst et al. 2000).

Patients with retropharyngeal abscess commonly present with neck pain, sore throat, fever, neck mass, respiratory distress or stridor and limitation of neck movement (Craig & Schunk 2003).

Physical examination may reveal bulging of the pharyngeal wall, pooling of saliva, swollen, and inflamed mucosa (Goldenberg et al. 1997).

Lateral neck radiograph may show loss of lordosis of the cervical spine, widening of the prevertebral soft tissue, and presence of air or foreign body in the soft tissue (Goldenberg et al. 1997, Craig & Schunk 2003, Boucher et al. 1999). Computerized Tomography (CT) scan is the preferred imaging technique since it helps in identifying the extent of the lesion and its relation to the important structures in the neck. It is useful in differentiating between cellulitis and abscess (Boucher et al. 1999).

Treatment of retropharyngeal abscess consists of securing the airway, intravenous antibiotics and intra oral incision and drainage (Goldenberg et al. 1997, Craig & Schunk 2003).

The aim of this study was to review demographic patterns, clinical presentations and management of RPA.

MATERIALS AND METHODS

Operative records from 2000 to 2007 were retrospectively reviewed from two ENT referral centers in Malaysia. All cases of RPA were included. Eight patients were identified. Patients' demographic information, presenting signs and symptoms were reviewed. Other findings which were reviewed are full blood count results especially the total white cell count, the culture and sensitivity results

which were obtained intra-operatively, the imaging findings which includes lateral neck x-ray and CT scan as well as the record of treatments which comprised of operative procedures and antibiotics.

RESULTS

In our series, the patients were predominantly female. There were five females and three males. The median age was 47 years old. The age group and sex distribution is illustrated in Table 1.

The presenting symptoms were varied and are summarized in Table 2. Most of the patients presented with dysphagia and or odynophagia, followed by shortness of breath with or without stridor, neck pain or swelling, restricted neck movement and hoarseness. Surprisingly, none of the patients had fever at the time of presentation.

Precipitating or predisposing factors are listed in Table 3. Four patients were diabetics. Being diabetics, these patients are prone to infection. Three patients had a history of fish bone ingestion. Among them was a 10 year old girl who was the youngest in the series.

Total white cell count was raised in all patients with predominantly neutrophilia. All patients underwent imaging studies. One patient underwent more than one imaging modalities i.e lateral neck radiograph and cervical contrast-enhanced computed tomography (CECT) scan which was suggestive for retropharyngeal abscess. Lateral neck radiograph mostly showed widening of prevertebral soft tissue, air in the soft tissue, foreign body and loss of cervical lordosis (Figure 1). CECT of neck confirmed the diagnosis and demonstrated ring enhancement and the extent of the abscess and its relation to important structures in the neck (Figure 2).

The patients were treated hydrated and medication was given to relief pain. Broad spectrum IV antibiotics were com-

Table 1: Age and sex distribution of the patients

Age (years)	Sex (no. of patient)		Total
	Male	Female	
0-10	-	1	1
11-20	-	1	1
21-30	-	-	-
31-40	-	1	1
41-50	1	-	1
51-60	1	-	1
61-70	1	-	1
71-80	-	2	2
Total	3	5	8

Table 2: Presenting symptoms

Symptoms at presentation	Number of patients (%)
Dysphagia/odynophagia	6 (75)
SOB/Stridor	3 (37.5)
Neck pain/ swelling	3 (37.5)
Restricted neck movement	1 (12.5)
Voice change	1 (12.5)

*Each patients may have one or more symptoms

Table 3: Precipitating / predisposing factors

Precipitating/predisposing factors	Number of patients (%)
Diabetes mellitus	4 (50)
Foreign body ingestion	3 (37.5)

menced based on most likely pathogens and surgeons preference. A combination of IV Rocephine and flagyl was used in one patient while IV cefuroxime and flagyl was administered to another patient. Other patients were treated with IV ampicillin and cavulanate. All patients underwent incision and drainage under general anesthesia.

Only two organisms were isolated from two patients in our study, i.e Klebsiella and Psuedomonas species, respectively. There were no growths in the rest of the patients. A Ziehl-Neelsen stain was performed in all patients, for which none tested positive.

Two approaches were performed i.e transoral approach and cervical approach

Table 4: Surgical technique

Surgical approach	Number of patients (%)
Intra –oral drainage	4 (50)
External drainage	3 (37.5)
Spontaneous rupture	1 (12.5)

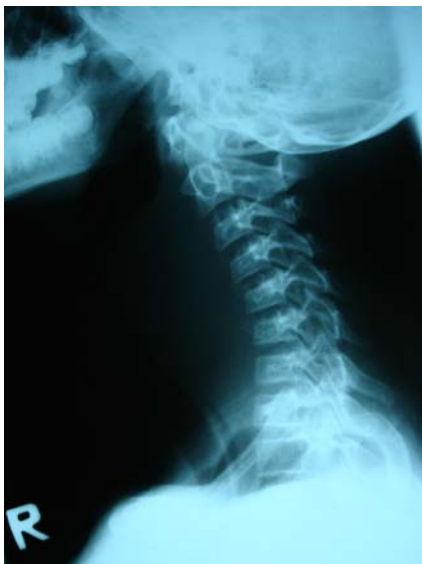

Figure 1: Lateral neck X – ray demonstrating increase prevertebral soft tissue space and loss of lordosis of cervical spine.

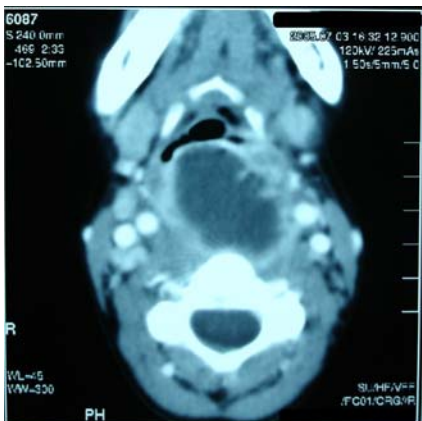


Figure 2: Contrast enhanced CT scan demonstrating a ring enhancement of retropharyngeal abscess.

(Table 4). Transoral approach was performed in four patients with bulging posterior pharyngeal wall and three patients

were treated with cervical drainage in view of the extension of the abscess laterally to the parapharyngeal space. One patient had spontaneous rupture of the abscess into the oral cavity while waiting for the operation.

Two patients who presented with airway obstruction underwent tracheostomy under local anesthesia. Tracheostomy tube were decannulated two days post-operatively. One patient underwent elective tracheostomy under general anesthesia for prolonged intubation secondary to septicaemia. Nasogastric tube was inserted in four patients who underwent intraoral drainage of abscess. The tube was kept for two days on average, post operatively.

All patients recovered well. Only one patient had septicaemia secondary to RPA and passed away on the thirteenth day of admission despite vigorous treatment.

DISCUSSION

RPA is common in children (Goldenberg et al. 1997). This is due to the fact that retropharyngeal nodes disappear by the age of five years. Most infections begin in the nose or nasopharynx, adenoids, and paranasal sinuses which drain to these nodes which later suppurate. There is a frequent history of an upper respiratory tract infection in children. In adults, retropharyngeal abscess are caused by instrumentation, foreign body and trauma, and interestingly it is also a manifestation of tuberculosis of cervical spine (Kamath et al. 2007).

In our series, seven out of eight patients were adults and the only child was aged 10 years. RPA in this child was secondary to fish bone ingestion. Perforation of the posterior pharyngeal wall by the fish bone would have caused RPA in this patient. Four of them had diabetes and they were generally prone to infection.

Acute RPA is characterized by fever, dysphagia, difficulty in breathing, stridor and torticollis in which the neck becomes stiff and the head is kept extended. Patients with chronic RPA also complain of dysphagia and discomfort in the throat. However, these symptoms are less marked. In our series, most of the patients presented with odynophagia and or dysphagia (75%), neck pain (37.5%) and difficulty in breathing or stridor (37.5%) as the abscess caused an obstruction to the airway and food passage. Examination commonly revealed bulging of posterior pharyngeal wall (Figure 3).

Sometimes, it is difficult to differentiate simple pharyngitis and RPA especially in the early stages of the disease whereby the signs and symptoms are not very prominent. We had one patient who was initially treated for pharyngitis. The presenting complaints were mild odynophagia and sore throat without fever. She was treated with oral antibiotics for a few days by her panel doctor.

Despite the administration of antibiotics, the symptoms persisted. She presented again with history of worsening sore throat and stridor without fever. She was intubated and blood investigation showed increased in total white cell count. CECT of neck was suggestive of RPA. The abscess was drained via cervical approach and *Klebsiella* species was isolated from the abscess. Unfortunately, she developed septicaemia. A tracheostomy was performed due to prolonged intubation. However, despite the vigorous treatment, the patient passed away. These masked symptoms in RPA could be attributed to partially treated RPA, improper antibiotics and inadequate duration of treatment.

The use of antibiotics has modified the presentation of deep neck space infections. Most of the patients who presented with deep neck space abscesses had already received some form of antibiotic therapy as an outpatient. Signs and symptoms of infection could be masked.

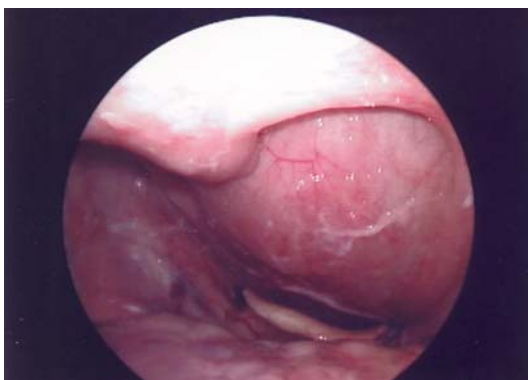


Figure 3: Laryngoscope view demonstrating bulging of posterior pharyngeal wall in one of the patients. The swelling is obstructing the laryngeal inlet.

This could result in missed or delayed diagnosis with development of complications.

Organisms which responsible in parapharyngeal abscess could be mixed aerobic and anaerobic. Among the aerobic organisms include streptococci, predominantly *Streptococcus viridans* and Beta-hemolytic streptococci (Page et al. 2008). Anaerobes are difficult to isolate and often are overlooked. Their exact role is difficult to ascertain from the medical literature because of the inconsistent methodologies used for their isolation and identification in many studies. Their isolation and identification requires appropriate methods of collection, transportation, and cultivation of specimens (Brook 2008). In our series, only two organisms were isolated from two patients, they were *Klebsiella* species and *Pseudomonas* species respectively. There was no growth in the rest of the patients. Anaerobe organisms could possibly be involved and as mentioned, it is difficult to detect such by culture and sensitivity study.

Soft tissue radiograph i.e. lateral neck radiograph in RPA is often diagnostic. It helps to localise the abscess in the neck and retropharynx (Flaup-Precaurariu et al. 2009). All radiographs must be in the true lateral position so that the preverte-

bral soft tissue could be measured correctly and must be obtained in maximum extension and in the inspiratory phase of respiration to prevent a false positive result. False positive radiographs commonly occur when an oblique view is obtained as well as during flexion of the neck in which the soft tissues bow into the airways. The lateral neck radiograph will demonstrate widening of prevertebral soft tissue, air in the soft tissue, foreign body and loss of cervical lordosis due to muscle spasm (Ameh 1999, Goldenberg et al. 1997). At the second cervical vertebral body level, soft tissue in excess of 7 mm in thickness is considered abnormal. At the sixth cervical vertebra, tissue thicker than 22 mm in adults or 14 mm in children is also considered to be abnormal. Sometimes, the widening of the prevertebral soft tissue may also be due to retropharyngeal cellulitis. Further evaluations with CECT scan are useful in differentiating an abscess from cellulitis (Goldenberg et al. 1997). It will show the extent of the abscess and its relation to important structures in the neck. Another non-invasive, inexpensive and reliable method is ultrasonography. It is capable in differentiating cellulitis from an abscess (Chao et al. 1999). All of our patients underwent imaging studies. Simple lateral neck radiograph and CECT neck were found to be useful investigative tools in the diagnosis of RPA in our patients. If CT suggests presence of frank pus, we proceeded for surgical incision and drainage (I&D) and if CT suggested a cellulitis we administered intravenous antibiotics therapy.

Most of the time, intubation is possible in patients with RPA. Intubation must be performed with great care to prevent rupture of the abscess and it is essential to have the head in a dependent position to prevent aspiration. However, in cases of difficult intubation due to the large swelling of the posterior pharyngeal wall which obstructs the view of the laryngeal

inlet, tracheostomy is indicated. In our series, two patients underwent emergency tracheostomy under local anesthesia due to upper airway obstruction at the time of presentation. A tracheostomy was performed to secure the airway in patients with large abscess.

Transoral incision and drainage together with intravenous antibiotics are the preferred treatments for retropharyngeal abscess (Ameh 1999, Craig & Schunk. 2003). It is performed under general anaesthesia since aspiration under local anaesthesia will worsen respiratory obstruction (Ameh 1999). We used two criteria proposed by Kirse & Roberson (2001) for safe transoral drainage. First, the abscess should be medial to the great vessels. Second, the abscess should be confined: there should not be free pus in the fascial spaces of the neck. If the lateral space is involved, cervical approach is required. For transoral drainage, the patient is positioned as for adenoidectomy. In our series, three of the patients underwent cervical incision due to the large RPA which extended to the parapharyngeal space. All of our patients underwent adequate incision and drainage with IV antibiotics coverage. Except one mortality, all of them fully recovered.

In conclusion, retropharyngeal abscess is a serious deep neck space infection with lethal complications. The diagnosis needs to be excluded in patients presenting with vague symptoms of sore throat and odynophagia without fever. Partially treated retropharyngeal abscess will mask the symptoms. Thus, thorough assessment of the patient is mandatory. A correct diagnosis should be achieved so that adequate treatment can be given to prevent mortality.

REFERENCES

- Ameh, E.A. 1999. Acute retropharyngeal abscess in children. *Ann Trop Paediatric*. **19**:109-112.

- Boucher, C., Dorion, D. & Fisch, C. 1999. Retropharyngeal abscesses : a clinical and radiologic correlation. *J Otolaryngol.* **28**:134-137.
- Craig, F.W. & Schunk, J.E. 2003. Retropharyngeal abscess in children: Clinical presentation, utility of imaging, and current management. *Pediatrics.* **111**: 1394-1398.
- Chao, H.C., Chiu, C.H., Lin, S.J. & Lin, T.Y. 1999. Colour Doppler ultrasonography of retropharyngeal abscess. *J Otolaryngol.* **28**:138-141.
- Furst, I., Ellis, D. & Winton, T. 2000. Unusual complication of endotracheal intubation: retropharyngeal space abscess, mediastinitis and empyema. *J Otolaryngol.* **29**(5): 309-311.
- Goldenberg, D., Golz, A. & Joachims, H.Z. 1997. Retropharyngeal abscess : a clinical review. *J Laryngol Otol.* **111**:546-550.
- Brook, I. 2008. Microbiology and antimicrobial management of head and neck infection in children. *Advances In Pediatrics.* **55**: 305-325.
- Kamath, M.P., Bhojwani, KM., Khamath, S.U., Mahabala, C. & Agarwal, S. 2007. Tuberculous retropharyngeal abscess. *Ear Nose Throat J.* **86**: 236-237.
- Kirse, D.J. & Roberson, D.W. 2001. Surgical management of retropharyngeal space infections in children. *Laryngoscope.* **111**:1413-1422.
- Page, N.C., Bauer, E.M. & Lieu, J.E.C. 2008. Clinical features and treatment of retropharyngeal abscess in children. *Otolaryngology, Head and Neck Surgery.* **138**: 300-306.
- Falup-Pecurariu, O. Leibovitz, E., Pascu, C. & Falup-Pecurariu, C. 2009. Bacteremic methicillin-resistant *Staphylococcus aureus* deep neck abscess in a newborn—Case report and review of literature. *International Journal of Pediatric Otorhinolaryngology.* **73**: 1824-1827.
- Pak, M.W., Chan, K.L. & van Hasselt, C.A. 1999. Retropharyngeal abscess. A rare presentation of nasopharyngeal carcinoma. *J Laryngol Otol.* **113**:70-72.
- Philpott, C.M., Selvadurai, D. & Banerjee, A.R. 2004. Paediatric retropharyngeal abscess. *J Laryngol Otol.* **118**:919-926.
- Siou, G. & Yates, P. 2000. Retropharyngeal abscess as a complication of oropharyngeal trauma in an 18-month old child. *J Laryngol Otol.* **114**:227-228.