

## CASE REPORT

## Doing Less is Better: Challenges in Complex Polytrauma Management - Case Report

FARAH NA, JOHAR MJ, ISMAIL MS

*Department of Emergency Medicine, Faculty of Medicine, Universiti Kebangsaan Malaysia Medical Centre, Jalan Yaacob Latif, Bandar Tun Razak, 56000 Cheras, Kuala Lumpur, Malaysia.*

### ABSTRAK

*Konsep resusitasi mengawal kerosakan yang terdiri daripada pemberian darah bagi tujuan resusitasi haemostatik, kawalan penghentian pendarahan dan dalam keadaan yang membenarkan, hipotensi terkawal dengan menghadkan pemberian cecair merupakan pendekatan yang berstruktur dalam rawatan pesakit dengan 'politrauma'. Sebaliknya jika pendekatan hipotensi terkawal digunakan dengan kehadiran rhabdomyolisis, ia boleh mengakibatkan kecederaan reperfusi-iskemia dan kecederaan ginjal akut yang akan memburukkan lagi keadaan. Kami laporkan kes politrauma yang melibatkan seorang lelaki berumur 20 tahun dengan kepatahan tulang pelvis terbuka disertai kecederaan pembuluh darah dan kecederaan iskemia anggota bawah sebelah kiri selepas digilis lori dalam kemalangan. Strategi hipotensi terkawal telah diberikan kepada pesakit empat jam sebelum rawatan pembedahan dijalankan di dewan bedah yang disusuli dengan pembedahan menghentikan pendarahan selama enam jam. Koagulopati, kecederaan ginjal akut dan rhabdomyolisis merupakan komplikasi dialami akibat kecederaan beliau. Pesakit gagal menunjukkan reaksi terhadap rawatan dan meninggal dunia tiga hari selepas kemalangan. Cabaran dan kekangan dalam merawat kecederaan politrauma yang kompleks serta bukti dapatan terkini berkaitan Resusitasi Mengawal Kerosakan akan kami bincangkan.*

*Katakunci: akut, ginjal, hipotensi terkawal, penghentian pendarahan, resusitasi mengawal kerosakan, resusitasi haemostatik, rhabdomyolisis*

### ABSTRACT

Damage control resuscitation, characterized by hemostatic resuscitation with blood products, rapid arrest of bleeding and when possible, permissive hypotension

**Address for correspondence and reprint requests:** Ismail Mohd Saiboon. Department of Emergency Medicine, Faculty of Medicine, Universiti Kebangsaan Malaysia Medical Centre, Jalan Yaacob Latif, Bandar Tun Razak, 56000 Cheras, Kuala Lumpur, Malaysia. Tel: +603-91459507 E-mail: fadzmail69@yahoo.com.my, ismail@ppukm.ukm.edu.my

with restricted fluid load form a structured approach in managing a polytrauma patient. When complicated with traumatic rhabdomyolysis however, permissive hypotension strategy may cause more harm resulting in subsequent ischaemic-reperfusion injury and acute kidney injury. We present a case involving a 20-year-old man who was rolled over by a lorry and sustained an open unstable pelvic fracture with vascular injury and left lower limb ischaemia. Permissive hypotension strategy was pursued for 4 hours prior to bleeding control in OT. This was followed by protracted surgery of 6 hours. Coagulopathy, acute kidney injury and rhabdomyolysis ensued in the post-operative period and patient succumbed to his injury on Day 3 post-trauma. Challenges and pitfalls in managing a complex polytrauma patient and recent evidences on damage control resuscitation is discussed.

**Keywords:** acute, damage control resuscitation, injury, kidney, polytrauma, permissive hypotension, rhabdomyolysis

---

## INTRODUCTION

Managing an unstable polytrauma patient is a challenging task as there are many aspects that need to be addressed immediately particularly in stabilizing patient's hemodynamics. It is a team management that requires everybody to play their role effectively and employ the correct treatment strategies. Damage control resuscitation forms a structured approach in the early management of the majorly injured. It is characterized by hemostatic resuscitation with blood components, rapid arrest of haemorrhage, and in specific situations, restrictive fluid administration with permissive hypotension (Giannoudi and Harwood 2016). It has been proven to be the most beneficial measure for treating trauma induced coagulopathy (Mizobata 2017). However, the use of this strategy should be carefully considered in certain circumstances

in which prolonged permissive hypotension might cause more harm. We describe a case of a 20-year-old male who sustained polytrauma as a result of a motor vehicle accident where permissive hypotension was instituted. However, he finally succumbed to acute kidney injury.

## CASE REPORT

A 20-year-old male was brought to a district hospital after being involved in a motor vehicle accident. He was run over by a lorry after he fell off his motorbike. He was trapped underneath the lorry for 30 minutes before he was extricated. He was initially resuscitated in a district hospital before being sent to a state general hospital, a level III trauma centre. He arrived at the centre 3 hours post-trauma. He was fully conscious and complained of pain over his pelvic region with loss of sensation of his left lower limb.

Airway and breathing was not compromised. He was pale and tachycardic with signs of poorly perfused peripheries. Per abdomen was soft and undistended. Pelvic compression test revealed an unstable pelvis. A circumferential pelvic splint was applied to the pelvis. There was a 3x3 cm wound over the left inguinal region. Examination of the spine was normal and anal tone was intact. There was a degloving wound over the left gluteal and perineal region involving the anal verge. His vital signs were; blood pressure (BP) 128/70 mmHg, heart rate (HR) 120/minute, respiratory rate (RR) 16 bpm, and SpO<sub>2</sub> 100% (with oxygen 3L/min via nasal cannula). Table 1 showed patient's vital signs while in district hospital and on arrival to the referral hospital.

Secondary survey revealed cold and dusky left foot with impalpable distal pulses and loss of sensation to touch and pain. Doppler signal were

absent at the left popliteal, posterior tibialis and dorsalis pedis arteries and monophasic at the left superficial femoral artery. There was frank haematuria in the urinary bag. There was over-riding prostate on per rectal examination but no scrotal hematoma. Focus Assessment with Sonography in Trauma (FAST) showed free fluid over the pelvic region. Pelvic X-ray showed open book pelvic fracture involving the left sacroiliac and left superior and inferior pubic rami.

His bloods investigations taken upon arrival to ED of the referral hospital were: hemoglobin (Hb) was 10 g/dL, venous blood gas (VBG) analysis showed metabolic acidosis with pH of 7.27, lactate of 4.1 mmol/L, pCO<sub>2</sub> of 22 mmHg, bicarbonate level of 15.2 mmol/L and base excess of -12.2. Urine output was 50 mls or 0.2 mls/kg/hour. He received 4 pints of crystalloids, 1 pint of colloid and 2 pints of packed cells (PC) in the district

Table 1: Patient's vital signs prior to arrival to Level III Trauma Centre

TIME	BP	HR	SPO2	RR	O <sub>2</sub>	NOTE
8.50 am	117/64	88	100	24	RA*	Temp 37 Blood glucose 13.9 mmol/L
9.05 am	121/83	100	100	25	RA	IM ATT 0.5 mls Urinary catheter inserted
9.25 am	114/73	132	100	25	RA	
9.35 am	107/79	122	100		RA	
9.45 am	120/75	130	100		RA	
9.50 am	115/71	122	100		Nasal cannula 3L	IV tramadol 100 mg
10 am	127/84	125	100		Nasal cannula 3L	IV maxolon 10 mg
10.10 am	153/90	124	100		Nasal cannula 3L	
10.20 am	175/83	120	100		Nasal cannula 3L	
10.50 am	122/71	122	100		Nasal cannula 3L	Arrived in Trauma Centre

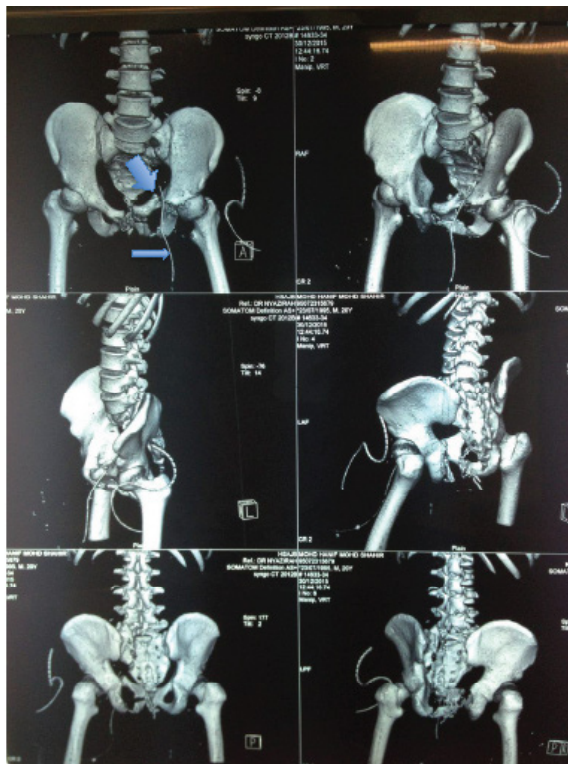


Figure 1: 3D reconstruction of CT pelvis of the patient. Thin arrow indicates suprapubic catheter that was used to catheterize the bladder. Thick arrow indicates fracture of the pelvis.

hospital and during the inter-hospital transfer. While in ED, his BP dropped to 74/50 mmHg and pulse rate increased to 140 bpm despite ongoing fluid and red blood cells transfusion. He needed emergency laparotomy and vascular repair but no operating theatre (OT) was immediately available. Resuscitation was continued in ED while awaiting OT availability. A further 1 pint packed cell and 2 pints fresh frozen plasma were transfused. Systolic blood pressure was maintained at 90mmHg while diastolic was at 60mmHg. The patient was transferred to OT after 1 hour in ED (4 hours post trauma).

Intra-operative findings were as follows: open pelvic fracture with transected left external iliac artery,

contused left common femoral artery and lacerated left external iliac vein. There was extraperitoneal bladder injury and rectal injury of more than 60% circumference with spillage of fecal content into the peritoneum. Left thigh and left leg were tense. Vascular repair with vascular graft was performed. Transverse colectomy with fashioning of stoma along with left thigh and left leg fasciotomies were done. Rectal drain and supapubic catheter were put in place. A further 4 pints of PC, 2 pints of fresh frozen plasma (FFP), 4 pints of platelets, 6 pints of cryoprecipitates and 5 pints of fluids were transfused during the 6 hours-long surgery.

By the end of surgery, patient

had severe metabolic acidosis with hyperkalemia; pH of 7.2, lactate was 5.7 mmol/L, bicarbonate was 15.1 mmol/L, base excess was -13 and potassium was 6.4 mmol/L. His urea increased to 20 mmol/L while creatinine was 150  $\mu$ mol/L, Hb was 9.6 g/dl, platelet was 100,000 per L while coagulation was deranged with INR value of 1.9 and PT ratio of 20 seconds. His urine myoglobin was raised at 32 mmol/L. 24 hours post-trauma, there was continuing absence of Doppler flow over the left popliteal, dorsalis pedis and posterior tibialis arteries with signs of limb ischaemia. Creatinine kinase was 80,000 IU/L and potassium was persistently over 5.5 mmol/L despite multiple boluses of intravenous calcium gluconate, insulin and sodium bicarbonate. He needed inotropic and vasopressor support. He was further transfused 8 pints of PC and 4 pints of platelet over the next 24 to 48 hours period. Urine output was around 1-2 ml/kg/hr. CT abdomen, pelvis and CT angiogram of the lower limbs (Figure 1) confirmed Tile's C unstable pelvic fracture and absence of opacification of left popliteal artery distally.

He was brought into the operating theater again at 36 hours post-trauma for above knee amputation of the left lower limb. He was started on continuous veno-venous hemodialysis at 48 hours post-trauma as creatinine kinase has risen to 92,000 IU/liter, urea to 24 mmol/L, creatinine to 420  $\mu$ mol/L, while phosphate and potassium to 2.8 mmol/L and 6.0 mmol/L respectively. The patient became hemodynamically unstable and required increasing inotropic

and vasopressor support. Although there was slight improvement in the metabolic parameter with hemodialysis, the patient's overall condition continued to worsen. He developed asystole and died at 70 hours post-trauma.

## DISCUSSION

This case highlights the challenges and pitfalls faced in the early management of a complex polytrauma case. Prehospital transfer, fluid resuscitation strategies, immediate OT availability and surgical approach all play important role in the patient's survival.

The first issue we would like to highlight is the transfer of patient from the scene to the point of definitive care. The benefit of transferring major trauma patients to higher level care have been demonstrated in several studies (Garwe et al. 2010). In this case, patient presented to the Emergency Department (ED) of the level III Trauma Center three hours post-trauma in decompensated hypovolemic shock. Although the transfer from the district hospital to the trauma center only took 30 minutes but the pit-stop made at the district hospital caused much unnecessary delay. It is concerning that the patient spent 2 hours in the district hospital without any major intervention being done. The delay may have occurred because of contacting the referral hospital and arranging for transfer and waiting for cross-match packed red blood cells to become available. Several studies from a developed country with well-developed trauma system has shown

favorable association between shorter pre-hospital time and outcome in the major trauma patients (Teixeira et al. 2007). Given that the referring hospital is only 30 minutes away, it might be a better strategy to directly transport this patient from the scene to the trauma center. This is in lieu with the recently updated European Guideline which recommends that severely injured patients be transported directly to a trauma facility (Rossaint et al. 2016). The major trauma networks in England put in place 'bypass protocols' that allow ambulances to proceed directly to trauma centers if certain injury pattern and physiological abnormality are present in trauma patients (Brohi et al. 2009) and we believe this protocols should be employed here and nationwide.

In the initial resuscitation period up till surgery, patient was transfused a total of 2 L of crystalloids, 0.5 L colloid, 3 pints PC and 2 pints of FFP. His systolic blood pressure was maintained at 90 mmHg in keeping with permissive hypotension (PH) strategy. Various randomized controlled trials conducted over the past decade have demonstrated that aggressive fluid resuscitation in the prehospital and hospital setting leads to more complications than hypotensive resuscitation, with disparate findings on the survival benefit (Carrick et al. 2016). This is done by restricting the crystalloid volume and at the same time, early administration of blood products in 1:1:1 ratio of red blood cells: fresh frozen plasma: platelets that resembles whole blood. The recently updated European Guidelines reflect

the findings from the randomized controlled trials. It recommends restricted volume replacement to a target systolic blood pressure of 80-90 mmHg until bleeding is controlled in trauma patients without brain injury (Rossaint et al. 2016). PH resuscitation strategy has been shown to significantly decrease post-operative coagulopathy and the risk of early post-operative death (Morison et al. 2011).

In the wake of traumatic rhabdomyolysis however, prolonged restricted volume replacement strategy may be detrimental. When large muscle bulk breaks down after trauma, the consequent reperfusion leads to both local and systemic complications (Better et al. 1990). Loss of circulating fluid secondary to bleeding and sequestration of fluid in the injured limb, compounded further by restricted volume therapy, can quickly push the patient into acute kidney injury (AKI). Associated complications are life-threatening dysrhythmias, hyperkalemia, metabolic acidosis and pulmonary edema. Managing the initial fluid therapy in the majorly injured patient with concomitant risk of developing rhabdomyolysis and AKI is complex. Wilcox and Oxley (Wilcox et al. 2002) reported a case of major trauma with exsanguinating hemorrhage and traumatic lower limb amputation who later developed rhabdomyolysis. The patient survived despite an initial pH of 6.57. This was attributed to immediate operative hemostasis coupled with restricted fluid administration before the surgery and vigorous restoration of organ perfusion strategy after bleeding is



arrested. The fact that the patient was rolled over causing entrapment should immediately raise the concern of compartment syndrome and rhabdomyolysis amongst the attending physicians. Hence the appropriateness of PH strategy in this patient need to be carefully balanced against the risk of AKI and its life-threatening complications.

Integral to DCR is damage control surgery (DCS); a concept of abbreviated surgery designed to prioritize short term physiological recovery over definitive anatomical reconstruction (Lamb et al. 2014). Its use has been associated with increased survival of the most injured patient with major hemorrhage and near exhausted physiological reserve (Rotondo et al. 1993). The aims of DCS are only to control haemorrhage and limit contamination. For major vascular injuries, vessel ligation or placement of temporary intravascular shunts were suggested in critical arteries as damage control options (Subramaniam et al. 2008). In extensive bowel injury, contamination control is key and lengthy bowel reconstruction and stoma creation are best avoided (Lamb et al. 2014). Attempts at primary definitive surgical management in patients with severe physiological compromise were shown to almost inevitably lead to poor outcome or unplanned abbreviation of the procedure (Lamb et al. 2014).

After restoration of blood flow to the ischaemic extremity, reperfusion per se result in local and systemic inflammatory response causing tissue injury that is in excess of the ischaemic insult alone (Eltzschig et al. 2004).

Ischaemic reperfusion injury, in its severest form, can cause multiorgan dysfunction and is a real threat to functional limb salvage and patient's survival. Although a few therapeutic strategies for ischaemic-reperfusion injury have been proposed, timely reperfusion and limiting the duration of ischaemia remain the cornerstone of clinical practice (Percival & Rasmussen 2011).

In this patient, his surgery started after 4 hours of trauma and lasted more than 6 hours wherein primary anatomical repair was attempted. With such lengthy surgery, his physiological parameters worsened as demonstrated by increasing lactic acidosis, coagulopathy and AKI. It is clear that DCS was not being executed in this patient despite having fulfilled the criteria. However from another viewpoint, primary vascular repair might has better chance at salvaging the patient's limb. Nevertheless, the old adage of 'Life over Limbs' continues to be relevant till today. Knowing fully well the local and systemic effects of reperfusion injury, left limb amputation may be considered in this patient during the first surgery.

## CONCLUSION

Mortality as a result of polytrauma remains high despite the advancement of time and technologies. Expedite transfer to trauma center with skilled escorts, early initiation of damage control resuscitation with emphasis on protocolized blood products administration, careful consideration of permissive hypotensive resuscitation

strategies, immediate trauma OT availability to arrest bleeding, and adhering to damage control surgery protocols are the major pitfalls and challenges in management. Local implementation of multidisciplinary, evidence based guidelines for management of bleeding trauma patient is likely to improve effective communication and mutual understanding between the different localities and specialties involved. In short, less time spent at the scene, shorter ED resuscitation, less fluid for resuscitation and doing less procedure during surgery is the cornerstone of severe polytrauma management. Sometimes doing less is more beneficial.

## REFERENCES

- Better, O.S., Stein, J.H. 1990. Early management of shock and prophylaxis of acute renal failure in traumatic rhabdomyolysis. *NEJM* **322**: 825-9.
- Brohi, K., Parr, T. Coats, T. 2009. Regional Trauma Systems: Interim Guidelines for Commissioners. On behalf of the Intercollegiate Group on Trauma Standards. London: Royal College of Surgeons.
- Carrick, M.M., Leonard, J., Slone, D.S., Mains, C.W., Bar-Or, D. 2016. Hypotensive resuscitation among trauma patients. *Biomed Res Int* **8901938**.
- Eltzschig, K., Collard, C. 2004. Vascular ischaemia and reperfusion injury. *Br Med Bull* **70**(1): 71-86
- Garwe, T., Cowan, L.D., Neas, B., Cathey, T., Danford, B.C., Greenawalt, P. 2010. Survival Benefit of Transfer to Tertiary Trauma Centers for Major Trauma Patients Initially Presenting to Nontertiary Trauma Centers. *AcadEmerg Med* **17**: 1223-32.
- Giannoudi, M., Harwood, P. 2016. Damage Control Resuscitation: Lessons learned. *Eur J Trauma Emerg Surg* **42**: 273-82.
- Lamb, C.M., MacGoey, P., Navarro, A.P., Brooks, A.J. 2014. Damage control surgery in the era of damage control resuscitation. *Br J Anaesth* **113**(2): 242-9.
- Mizobata, Y. 2017. Damage Control Resuscitation: A practical approach for severely haemorrhagic patients and its effect on trauma surgery. *J of Intensive Care* **5**: 4.
- Morison, C.A., Carrick, M.M., Norman, M.A., Scott, B.G., Welsh, F.J., Tsai, P., Liscum, K.R., Wall, M.J.Jr., Mattox, K.L. 2011. Hypotensive resuscitation strategy reduces transfusion requirements and severe postoperative coagulopathy in trauma patients with hemorrhagic shock: preliminary results of a randomized controlled trial. *J Trauma* **70**(3): 652-63.
- Percival, T.J., Rasmussen, T.E. 2011. Reperfusion strategies in the management of extremity vascular injury with ischaemia. *Br J Surg* **99** (Suppl 1): 66-74.
- Rossaint, R., Bouillon, B., Cerny, V., Coats, T.J., Duranteau, J., Fernandez-Mondejar, E., Filipescu, D., Hunt, B.J., Komadina, R., Nardi, G., Neugabauer, A.E.M., Ozier, Y., Riddez, L., Schultz, A., Vincent, J., Spahn, D.R. 2016. The European Guideline on management of major bleeding and coagulopathy following trauma: fourth edition. *Critical Care* **20**: 100
- Rotondo, M.F., Schwab, C.W., McGonigal, M.D., Philips, G.R., Fruchterman, T.M., Kauder, D.R., Latenser, B.A., Angood, P.A. 1993. Damage control: an approach for improved survival in exsanguinating penetrating abdominal injury. *J Trauma* **35**: 375-82.
- Subramanian, A., Vercruyse, G., Dente, C., Wyrzykowski, A., King, E., Feliciano, D.V. 2008. A decade's experience with temporary intravascular shunts at a civilian level 1 trauma center. *J Trauma*, **65**: 316-24.
- Teixeira, P.G., Inaba, K., Hadjizacharia, P., Brown, C., Salim, A., Rhee, P., Bowder, T., Noguchi, T.T., Demetriades, D. 2007. Preventable or potentially preventable mortality at a mature trauma center. *J Trauma* **63**: 1338-46.
- Wilcox, N., Oxley, P. 2002. Survival with an arterial pH of 6.57 following major trauma with exsanguinating haemorrhage associated with traumatic amputation. *Resuscitation* **53**(2): 217-21.

Received: 19 Sept 2017

Accepted: 8 May 2018