

CASE REPORT

A Black Finger Does Not Equal A Dead Finger

SHALIMAR A, WILLIAM H, LEVIN KB, PARMINDER GS, NUR
AZUATUL AK, TAN JA, AHMED SUPARNO BM

Hand and Microsurgery Unit, Department of Orthopaedics and Traumatology, Faculty of Medicine, Universiti Kebangsaan Malaysia, Medical Centre, Jalan Yaacob Latif, Bandar Tun Razak, 56000 Cheras, Kuala Lumpur, Malaysia.

ABSTRAK

Pembedahan revaskularisasi dan replant kadang-kadang memberi keputusan yang tidak memuaskan. Kami memaparkan dua kes amputasi jari separa. Kes pertama adalah pesakit lelaki berumur 11 tahun di mana jari hantu tengah telah terpental di dalam mesin pembasuh baju dan tertarik putus hanya bersambung dengan otot flexor digitorum profundus. Kes kedua adalah pesakit lelaki berumur 42 tahun yang ditetak parang di tangan kirinya menyebabkan separa terputus jari kecil dan jari manis hanya bersambung dengan kulit selebar 2 cm. Kedua-dua pesakit menjalani pembedahan revaskularisasi satu arteri digital untuk setiap jari kerana arteri digital yang sepasang rosak. Vena digital tidak di perbaiki. Rawatan untuk kesesakan pendarahan vena dilakukan dengan mencucuk hujung jari dengan jarum enam kali sehari selama satu minggu. Pada 1 minggu selepas pembedahan, jari kelihatan hitam tetapi mempunyai bentuk yang baik dan kental bila dipicit serta mempunyai pendarahan merah arteri apabila dicucuk jarum. Pakar bedah yang kurang pengalaman mungkin menganggap ini adalah kematian jari dan ingin amputasi jari. Namun kami menunggu selama sebulan dan kelihatan kulit hitam jatuh dan di ganti kulit baru yang merah dan baik.

Kata kunci: amputasi, hitam, iskaemia, pembedahan replant, revaskularisasi

ABSTRACT

Revascularisation and replant surgery occasionally produces sub-optimal results. We present two cases of near total amputation of the digits. The first patient was an 11-year-old boy with a middle finger avulsion injury sustained after the finger was caught in a washing machine with the flexor digitorum profundus still attached. The second patient was a 42-year-old male who sustained a machete attack and had near total amputation of his small and ring fingers with a 2 cm skin

Address for correspondence and reprint requests: Assoc. Prof. Dr. Shalimar Abdullah. Hand and Microsurgery Unit, Department of Orthopedics and Traumatology, Faculty of Medicine, Universiti Kebangsaan Malaysia Medical Centre, Jalan Yaacob Latif, Bandar Tun Razak, 56000 Cheras, Kuala Lumpur, Malaysia. Tel: +603-91456005 Email: kelapa44@yahoo.com

bridge still attached. All patients underwent revascularization with repair of only one digital artery for each finger as the opposite artery was non-viable. No digital veins were repaired. Relief of venous congestion was done by pin-prick six times a day up till one week. At one week post-surgery, the fingers were discoloured black but had good pulp turgor and full contour with arterial bleed on pin-prick. Inexperienced surgeons may view this as gangrene and amputate the fingers. However, we continued observation and at one month post-surgery, the black skin had desloughed and the underlying skin was pink.

Keywords: amputation, black, ischaemia, replantation, revascularization

INTRODUCTION

Amputation of fingers is not a life-threatening event but it does cause functional and psychological problems that can lead to a decrease in quality-of-life. Despite microsurgical and technical advances, it is still difficult to achieve satisfactory functional results in cases of replantation (Oruc et al. 2014). However, it is widely accepted that replantation is not always the best option in the case of a severed finger (Casal et al. 2013).

There are numerous factors to be considered when deciding on a replantation or revascularization surgery. They include the actual tissues to be replanted, the patient's general medical condition and less obvious factors are the social, economical and psychological aspects. Despite numerous steps and procedures, replantation remain the prime indication for treatment of amputated fingers, due to functional and aesthetic advantages (Yoshimura 2003).

CASE REPORT

Case 1

An 11-year-old boy had his right middle finger caught in a washing machine sustaining an avulsion near total amputation injury. The finger was only attached by the flexor digitorum profundustendon. Intra-operatively, the neurovascular bundle was examined under microscope. The ulnar digital vessel and both digital nerves were damaged. Only the radial digital artery was anastomosed. We were unable to find a vein for anastomosis. Post-repair, the finger was very congested and we had to proceed with 4 hourly pin-prick to relieve the congestion. There was arterial bleed at each pin-prick. We did not have availability of leeches for decongestion. We continued pin-prick up till 1 week post-operation.

At 1 week post-anastomosis, distal to the proximal interphalangeal joint, the fingertip and dorsal skin was all black (Figure 1). However the pulp turgor was good and there was arterial bleed on pin-prick. Additionally in view of the young age of the patient, we decided not to amputate the finger and to review patient in the clinic weekly.

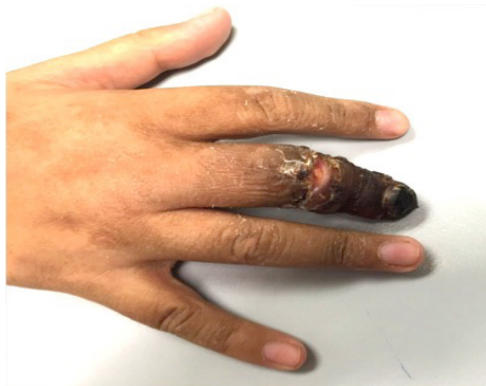

Figure 1: Post-revascularisation at 7 days: The skin of the middle finger remained black from the proximal interphalangeal joint to the tip

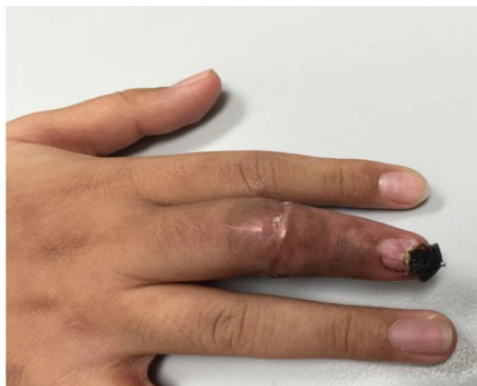

Figure 2: Post-revascularisation at 7 weeks: The skin has turned into a normal pink colour with just a tip of necrotic tissue

The condition of middle finger of the patient actually slowly improved every week. At 7 weeks post-operative, we were delighted to see new pink skin as the black, dry skin had desloughed off (Figure 2). At 3 years follow-up, he had excellent function and cosmetically good outcome. Nevertheless the finger was shorter than normal and sensation was reduced at 2/10. Motion was also reduced with 0-45 degree active motion at the proximal interphalangeal joint and a fused distal interphalangeal joint (Figure 3).

Case 2

A 42-year-old male sustained a machete attack with a near total amputation of his right small and ring finger attached only by 2 cm of dorsal skin with a jagged wound. His fingers were dusky and capillary refill time was more than 4 seconds. We proceed with revascularisation of both his fingers. Only one digital artery to each finger was anastomosed intra-operatively. However, the quality of the digital artery was questionable.

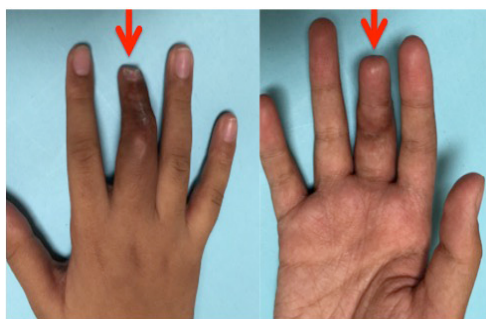


Figure 3: Post-revascularisation at 3 years: Excellent function with good cosmesis except finger is short due to destruction of growth plate at the distal interphalangeal joint.

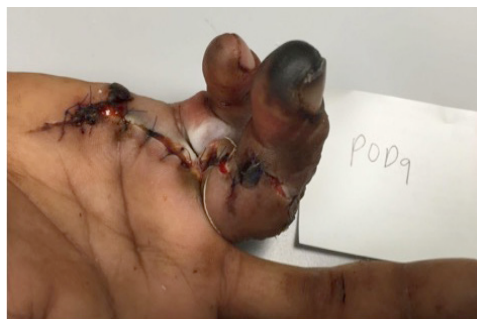

Figure 4: Post-revascularisation at 9 days: (View from the radial aspect) The skin was wet, macerated, discoloured and appeared unhealthy

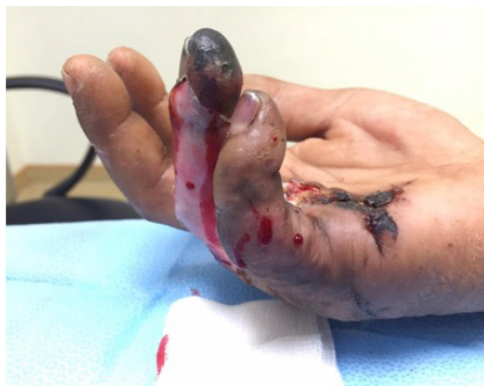

Figure 5: Post-revascularisation at 16 days: (View from the ulnar aspect). The skin of the ring and middle fingers have revascularised and turned pink

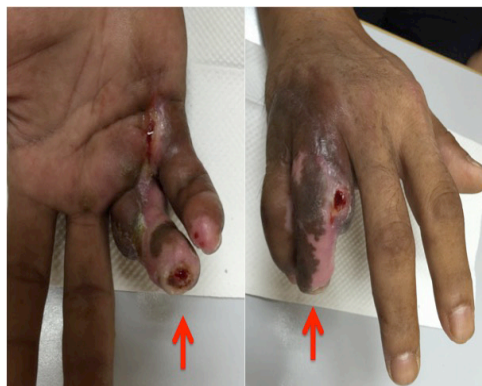

Figure 6: Post-revascularisation at 4 months: Fingers are pink with some hypopigmented region. Serous discharge seen from part of the wound.

We were not able to anastomose the other two digital arteries. The digital veins were not repaired due to time constraint and the presence of the skin bridge.

At post-operative day 9, the fingers developed blistering, the wound looks wet and the skin appeared unhealthy (Figure 4). The pulp was black although pulp turgor was maintained. Pin-prick bled red arterial bleeding. We decided to wait for demarcation of the fingers rather than deciding for amputation. We reviewed this patient weekly in clinic. At 16 days post-operative, the pulp is still black but the skin over the proximal and middle phalanx was pink and healthy (Figure 5). At 4 months follow-up, he still had minimal serous discharge from the wound (Figure 6). His function was poor with stiffness and hypoaesthesia. Although we had advised him to stop smoking to accelerate wound healing he was unable to do so. He was also non-complaint to physiotherapy.

DISCUSSION

For a total amputation, it is vital to preserve the amputated part well to ensure a successful surgery. However, with near total amputation, it is less commonly known that the nearly amputated segment should be preserved as well. Cases where the digit or limb is hanging by a sliver of skin should still be preserved by wrapping it in a saline-moistened gauze. A plastic bag sealed with ice in it should be placed adjacent to the digit or limb and then the whole area bandaged to keep the ice in place. A thick bandage can be applied to the other exposed areas if the patient complains that the ice is too cold. However it is imperative to begin the cold ischaemic time as soon as possible for the near total amputated segment which has no blood supply (Maricevich et al. 2011).

The decision to attempt replantation is based on the discretion of the attending surgeon and include the following factors: amputation of the

thumb, multiple-digit amputations, time from injury to arrival, appropriate transportation and condition of the amputated part (absence of a high degree of tissue damage, such as the ribbon sign), and medical stability to undergo replantation (Fufa et al. 2013).

The final judgment of whether to replant or revascularise the arteries and veins is determined after microscopic inspection of the vessels and nerves is complete. Once committed, it is the attention to detail that will determine function; bone shortening and rigid fixation, multiple strand flexor tendon repair, repair of the extensor mechanism to permit early movement, periosteal approximation to aid gliding, radical debridement and primary skin closure (Morrison & McCombe 2007).

There are many reasons to suspect a failing digital replantation or revascularization. One of the main areas is early recognition of vascular compromise. There can be arterial insufficiency or occlusion and venous occlusion. A pale or dusky finger points to arterial occlusion. Pulse oximetry and temperature will decrease in comparison to other digits. Tissue turgor in the pulp will increase but there will be absence of bleeding when a needle is poked into the pulp of the finger. Measures taken include ensuring an optimal blood pressure, placing the finger in a dependent position and prescribing anticoagulants to the patient. Failure of these measures will require immediate re-exploration with repeat anastomosis or a vein graft of the digital vessel (Maricevich et al. 2011).

With venous obstruction, the finger

turns blue or purple and is swollen and looks congested. Venous obstruction is more detrimental compared to arterial occlusion due to toxin accumulation and breakdown of metabolites (Maricevich et al. 2011). Treatment measures include usage of medicinal leeches, removal of nail plate and heparin swab at the nail bed, fingertip incision with heparin swab and pin-prick of the pulp. In both of our cases, we utilized a 4-hourly pin-prick of the pulp which resulted in bright red arterial bleed even though the pulp was black in colour.

There exists more complicated methods to relieve venous congestion such as flaps eg proximally based cross finger flap but these tend to be surgically demanding (Zhao et al. 2011).

At one week post-revascularisation, both of our cases still had a viable finger as evidenced by the good pulp turgor and arterial bleed on pin-prick even though the finger was black in colour. At this point, we felt that our fingers will continue to survive. Replanted digits surviving at least 1 week following surgery rarely succumb to ischaemic necrosis. However, there are reports of non-viable fingers at 16 days of viability and at 3 weeks follow-up (Duffy et al. 1998). Our first case survived well until even at 3 years follow-up with excellent function and satisfactory cosmesis. Our second case survived to four months before being lost to follow-up. No doubt, age as a factor had a big role in the healing of our patients.

CONCLUSION

Pulp turgor and not discolouration is an important factor in assessing viability of the finger. The benefit of the doubt should be given in replantation or revascularization surgery. We should always observe the digits before proceeding for amputation. If the pulp turgor is present but the skin is black, we can observe closely for a few weeks as the finger may survive.

REFERENCES

- Casal, D., Gomez, M.M., Antunes, P., Candeias, H., Almeida, M.A. 2013. Defying standard criteria for digital replantation: A case series. *Int J Surg Case Rep* 4(7): 597-602.
- Duffy, F.J., Concannon, M.J., Gan, B.S., May J.W. 1998. Late digital replantation failure: pathophysiology and risk factors. *Ann Plast Surg* 40(5): 538-41.
- Fufa, D., Calfee, R., Wall, L., Zeng, W., Goldfarb, C. 2013. Digit replantation: experience of two U.S. academic level-I trauma centers. *J Bone Joint Surg Am* 95(23): 2127-34.
- Maricevich, M., Carlsen, B., Mardini, S., Moran S. 2011. Upper extremity and digital replantation. *Hand* 6(4): 356-63.
- Morrison, W.A., McCombe, D. 2007. Digital replantation. *Hand Clin* 23(1): 1-12.
- Oruc, M., Gursoy, K., Ozer, K., Aslan, O.C., Kankaya, Y., Sungur, N., Ulusoy, M.G., Kocer, U. 2014. Digit Replantation of eight years' experience: demographic characteristics and outcomes. *J Reconstr Microsurg* 30: A112.
- Yoshimura, M. Indications and limits of digital replantation. 2003. *JMAJ* 46(10): 460-7.
- Zhao, J., Abdullah, S., Li, W.J., Appukuttan, A., Tien, H.Y. 2011. A Novel solution for venous congestion following digital replantation: a proximally based cross-finger flap. *J Hand Surg Am* 36(7): 1224-30

Received: 5 Jul 2018

Accepted: 28 Nov 2018