

**Case report****Anomalous Pulmonary Fissural Anatomy of the Right Lung- A Case Report**

Arora J (✉), Kumar A, Kumar Ravi Satish, Mehta V, Suri RK, Rath G

Vardhman Mahavir Medical College & Safdarjang Hospital, New Delhi

**Abstract**

Anatomical knowledge of variations of lobes of lung is important for accurately identification of broncho-pulmonary segments. It is of great significance for radiologists during interpretation of X-ray and CT scans. Such studies are of utmost importance during lobectomies and surgical resection of individual segments of lung. The present paper highlights the abnormal sinuous pattern of oblique fissure and incomplete horizontal fissure in right lung. It also describes in detail the morphology of an abnormal pyriform lobe present between these two fissures. We as anatomists wish to draw attention to abnormal morphological patterns of fissures of lungs which may be of utmost importance for radiologists and surgeons and add to the already existing knowledge of lobar anatomy.

**Keywords:** oblique fissure, horizontal fissure, sinuous, lingual lobe, pyriform

**Correspondence:**

Dr.Jyoti Arora, Department of Anatomy, Vardhman Mahavir Medical College & Safdarjang Hospital, New Delhi, India.  
Tel: 9999077775, Email: jyotiarora2005@yahoo.co.in

Date of submission: 1<sup>st</sup> Aug 2011

Date of acceptance: 23th Sept 2011

Date of publication: 3<sup>rd</sup> Oct 2011

**Introduction**

Incomplete fissures of lung are a common observation in lung specimens, but are often misinterpreted on radiographs and computed tomographic (CT) scans. Anatomical knowledge of the fissures and the lobes of the lung is imperative for lobectomies and surgical resection involving individual segments.

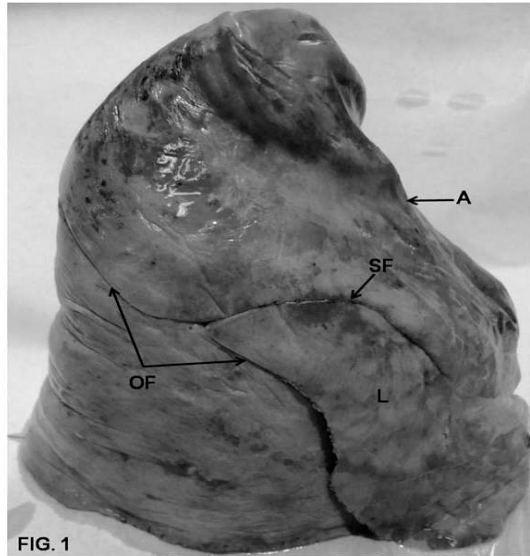
The present case describes abnormal sinuous pattern of oblique fissure and incomplete horizontal fissure in the right lung. An abnormal pyriform lobe was observed between these two fissures. The resultant anomalous lobar pattern may be of enormous interest to the present day radiologists, surgeons and medico-personal.

An incomplete fissure is a cause for post-operative leakage (1) while an accessory fissure may act as a barrier to infection spread. The resultant sharply marginated pneumonia may be wrongly interpreted as atelectasis or consolidation (2).

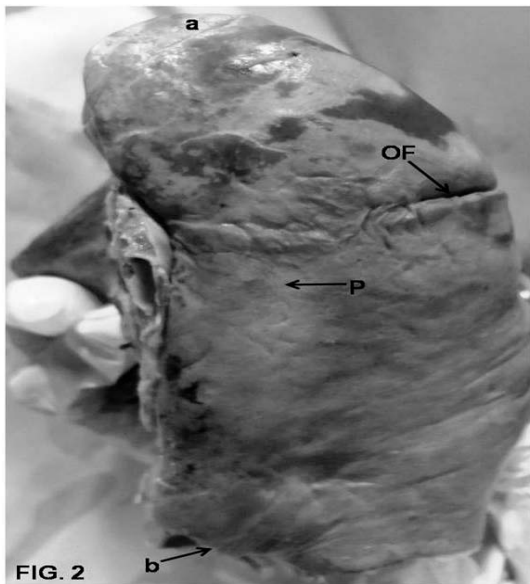
The present case is an attempt to highlight the clinical importance and embryological basis of such incomplete and accessory fissures resulting in anomalous lobar pattern.

**Case Report**

During educational programme of undergraduate students, an unusual lobation of right lung was observed. The oblique fissure of right lung cut the posterior border of lung, 6.5cms from the apex of lung. Commencement of a sinuous fissure was recorded, from the oblique fissure, at a distance of 5.3cms from the posterior border. This sinuous fissure divided the oblique fissure into a cranial part and a caudal part. The curvature of the oblique fissure was oblique in the cranial part and convexo-concave in its caudal part, distal to the commencement of the sinuous fissure. The oblique fissure hence, traversed a curvaceous route, inferior to the commencement of sinuous fissure. The oblique fissure could be traced to a point 1.3cms distal to the lower end of hilum.



**Figure 1:** Right lung showing the oblique fissure, abnormal sinuous fissure and pyriform lobe. (OF-Oblique Fissure, SF-Sinuous Fissure, A-Anterior Border, L- Lingual lobe)



**Figure 2:** Right lung showing the incomplete extent of the oblique fissure. (OF-Oblique Fissure, A-Anterior Border, a-Apex, b- Base)

The course of the sinuous fissure was forward, upward, downwards and then forwards again. The sinuous fissure was well defined in its proximal part but at a distance of 3.5cms from the anterior border of right lung it was ill defined in the distal part of its course. A pyriform shaped lingual lobe was delineated between the oblique and the sinuous fissure. The maximum height of this pyriform shaped lingual lobe was 9.3cms and the maximum width was 5.7cm.

The distance between lower end of oblique fissure and the anterior border of right lung was 5cm. The distance between the anterior end of sinuous fissure and the inferior border of right lung was 3.7cms. The left lung did not display any abnormal orientation of fissures.

## Discussion

The right lung is divided into superior, middle and inferior lobes by two fissures, an oblique and a horizontal. The upper, oblique fissure separates the inferior from the middle and superior lobe and corresponds closely to the left oblique fissure although it is less vertical, crossing the inferior border of the lung about 7.5cms behind its anterior end. On the posterior border it is level with the spine of 4th thoracic vertebra or slightly lower. It descends across the 5th intercostal space and follows the 6th rib to the 6th costochondral junction.

The short horizontal fissure separate the superior and middle lobes, passing from the oblique fissure, near the mid axillary line, horizontally forwards to the anterior border of the lung, level with the sternal end of the 4th costal cartilage, on the mediastinal surface it passes backwards to the hilum. The small middle lobe is thus uniform and includes some of the costal surface, the lower part of the anterior border and the anterior part of the base of the lung. (3)

Knowledge of variations of incomplete fissures and lobes of lung is important for preoperative planning strategy for pulmonary lobectomy and segmental resection of lung.(4). Incomplete fissure may also alter the root of spread of lung disease (5). The differential diagnosis of the fissure includes margins of costal cartilages (6), basal scars, a basal pneumothorax (7), walls of bullae and major fissure (8).

Anatomical knowledge of fissures of lung helps in differential diagnosis of chest diseases in case of extension of fluid into an incomplete major fissure or spread of diseases through different pathways (9). Studies have proved that incidences of superior accessory fissure are higher in right lung compared to the left one (10). Incomplete fissures as recorded in the present case are often mistaken for the appearance of pleural effusion. Interestingly, the incomplete horizontal fissure in the present case also described an abnormal sinuous course and along with sinuous course of lower part of oblique fissure, also described an anomalous pyriform lobe between them. The incompetence, thick sections and orientation of fissures may obscure them during radiographic procedure and increase clinicians dilemma (11).

During foetal life as the lung develops, the spaces of fissures that separate individual bronchopulmonary buds or segments become obliterated except along the oblique and horizontal fissures (12). Incomplete fissures could be result of abnormal obliterations of these fissures, partially or completely.

It is proven fact that lymphatics of the lung drain centripetally from the pleura towards hilum (13). In the present case, an abnormal sinuous course of horizontal fissure and lower part of oblique fissure would mean an anomalous or altered course of visceral pleura, thereby changing the course and arrangement of lymphatic drainage. An incomplete horizontal fissure as observed in the present case could be mistaken for a scar or a pleural line made visible by pneumothorax.

We as anatomists opine that, it is essential to keep in mind during clinical evaluation, such fissures, which may be easily mistaken for the above mentioned conditions.

#### References

1. Walker WS & Craig SR. A proposed anatomical classification of the pulmonary fissures. *J R Coll Surg Edinburgh* 1997; 42(4):233-4.
2. Godwin JD & Tarver RD. Accessory Fissures of the Lung. *AJR* 1985; 144(1):39-47.
3. Williams PL. *Gray's Anatomy*. 38<sup>th</sup> Edition. Philadelphia: Churchill Livingstone, 2000, Pg. 1659.
4. Modgil V, Das S, Suri R K. Anomalous lobar pattern of right lung- A case report. *Int J Morphol* 2006; 24(1):5-6.
5. Meenakshi S, Manjunath K, Balasubramanyam V. Morphological Variations of the Lung Fissures and lobes. *The Indian J of Chest Diseases & Allied Sciences* 2004; 46(3): 179-82.
6. Trapnell DH. The differential diagnosis of linear shadows in chest radiographs. *Radio clin North Am* 1973; 11(1): 77-92.
7. Graberger G. Beitrag Zur Kenntnis der kasalen paramediastinalen Dreieckschatten. *Acta Radiol* 1931; 12: 240-253.
8. Simon G. The cause and significance of some long line shadows in the chest radiograph. *Proc R Soc Med* 1965; 58(11 part 1): 861-866.
9. Dandy WE. Incomplete pulmonary interlobar fissure sign. *Radiology* 1978; 128(1):21-5.
10. David Godwin J and Robert D. Traver. Accessory fissures of the lung. *AJR* 1985; 144(1):39-47.
11. Das S, Latiff AA, Othman FB et al. Topographical anatomy of anomalous oblique fissure and lingual of the lung. *Braz J Morph Sci* 2007; 24(3):155-56.
12. Larson WJ. *Human Embryology*. New York: Churchill Livingstone, 1993, 111-30.
13. Ellis H. *Clinical Anatomy. A revision and applied anatomy for clinical students*. 10<sup>th</sup> ed. USA: Blackwell Publishing, 2002.