

Original Research Article**Histomorphometric Analysis of Dermal Collagen and Elastic Fibres in Skin Tissues Taken Perpendicular to Each Other From Head and Neck Region**Naveen K¹, Pramod K², Keerthana P³, Satheesha NB¹, Ranjini K⁴, Raghuvver CV⁵

¹Department of Anatomy, Melaka Manipal Medical College (Manipal Campus), ³Department of Information Science, Manipal School of Information Science, ⁴Department of Pathology, Kasturba Medical College, Manipal University, Manipal, Karnataka State, 576104, India.

²Department of Plastic Surgery, King Abdul Aziz Hospital, Sakaka- 42421, Al-Jouf, Ministry of Health, Saudi Arabia.

⁵Department of Pathology, Yenepoya University, Deralakatte Mangalore, Karnataka State, 575018, India.

Abstract

To find the anatomical cause difference in scar appearance in different direction of the same region, the distribution of collagen and elastic tissue between the sections taken in two orientations perpendicular to each other from head and neck region were studied. Total of 120 skin samples taken from five different areas of head and neck region in two directions from 12 cadavers were processed and stained with special stain Verhoeff-van Gieson stain. Quantitative fractions of collagen and elastic fibres were measured by image analysis using tissue quant software Version 1.0. There was a significant differences of quantitative fractions of collagen and elastic tissue between horizontal and vertical direction in areas where skin was thick and tight (scalp and forehead with $p < 0.01$). Relatively thinner and loose areas of skin (submandibular area, neck) showed statistically significant asymmetrical distribution of elastic tissue only ($p < 0.01$). In very thin and loose skin (lateral canthal area), the difference in distribution of both collagen and elastic tissue was not statistically significant. Asymmetrical distribution of dermal collagen and elastic tissue in two directions of the sections in the same region could be one of the causes of difference in the appearance of scar placed in different directions of the same region.

Keywords: Quantitative fraction, tissue-quant, dermal collagen, dermal elastic, histomorphometry

Correspondence:

Dr. Pramod Kumar, Department of Plastic Surgery, King Abdul Aziz Hospital, Sakaka- 42421, Al-Jouf, Ministry of Health, Saudi Arabia. Tel: 00966 551521514 Fax: +966-2-6951996 Email: pkumar86@hotmail.com

Date of submission: 10 Oct, 2013

Date of acceptance: 27 April, 2014

Introduction

Collagen is the most abundant protein in the human body. Though they are found throughout the body, their types and organization are dictated by the structural role plays in a particular region or structure. In the skin, despite of being the major content of the dermis, the collagen displays morphologically different texture both in reticular and papillary layers. Normal adult human skin contains type I and type III collagen in an approximate 6:1 ratio. With age, the ratio becomes smaller as the proportion of type III collagen increases, probably due to impaired synthesis

of type I collagen in aged skin (1). Biochemically, the papillary dermis is composed of type III collagen and reticular dermis composed of type I collagen. Normal adult skin predominantly consists of type I collagen in entire dermis. However, the skin of the human foetus contains large percentage of type III collagen, in contrast to the skin of adult (2).

Structural components of elastic fibres of the dermis are the micro fibrils and matrix elastin. Microfibrils accounts for 15% of elastic fibre, whereas elastin makes up 85% of the fibre. Histologically, it is the elastin that stains with elastic tissue stains. Elastic

fibres undergo extensive changes during life. These changes generally represent aging and or elastic degeneration due to chronic sun exposure. In aged persons, the fragmentation and disintegration of elastic fibres may be observed (2).

Scar appearance following the wound repair is a natural process. Both collagen and elastic fibres play key role in the process of wound healing and subsequent consequences resulting in the formation of the scar. This is because of the fact that, scar tissue is composed of same collagen but with differences in arrangement pattern and composition (3). Studies also proved the role of elastic fibres in the process of improvement of scar appearance along with better wound healing outcomes by using elastin based dermal substitutes (4).

For centuries, surgeons have been looking for the best direction to follow in making elective incision so as to obtain most aesthetic and functional scar. It is an universal fact that, if an incision follows a certain direction on the skin, a better scar will be obtained than if it is at right angles to that direction. There are several concepts of skin lines have been put forward. But, Langers line is the line of choice in surgical approach which explains the orientation of collagen fibres in the dermis. Unfortunately, it still remains mysterious and challenging task for the aesthetic surgeons to minimize the scar appearance and the behaviour. Study on this concept suggested the role of dermal connective tissue fibres in terms of their differential content in different regions of the body might have significant role in addition to concept of Langer's line (5). Therefore, evaluation of quantitative fraction of dermal collagen and elastic fibres in skin sections taken perpendicular to each another (horizontal and vertical) from different parts of the head and neck region is paramount for the aesthetic surgeons in the attempt to produce better aesthetic result as this region has more cosmetic value than any other.

Materials and Methods

The present study was carried out on formalin embalmed cadavers with the approximate age ranging between 50 to 60 years. A total of 120 skin samples obtained from five areas of the head and neck region from 12 cadavers. From each area of chosen, elliptical (1x0.5cm) skin sections were collected in two directions. First sample was taken in 'horizontal' direction while second sample was taken across the former and considered as 'vertical' directed sample.

Sample collection

Specific area of sample collection was chosen randomly and uniformity was maintained.

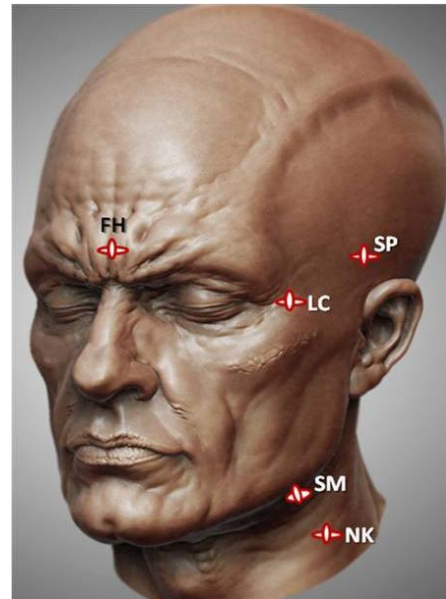


Figure 1: Showing topographic position of sample collected. SP: Scalp, FH: Forehead, LC: Lateral canthus, SM: Submandibular area, NK: Neck (Adapted from CGSociety.org)

Topographic areas on the head and neck region where the skin samples were taken are as follows (Fig. 1):

1. **Scalp:** About 4 to 5 cm above the attachment of root of the auricle in the temporal region.
2. **Forehead:** At the midline of forehead about 2 to 3 cm above the root of the nose.
3. **Lateral canthus:** 1-2 cm lateral to the lateral canthus
4. **Submandibular area:** Slightly oblique section taken from the submandibular region about 1cm below and medial to angle of the mandible. Section taken near parallel to skin crease was considered horizontal and the section perpendicular to it was considered as vertical.
5. **Neck:** At the midpoint on neck which is marked by an imaginary line extending vertically from neck of the mandible to midpoint of clavicle.

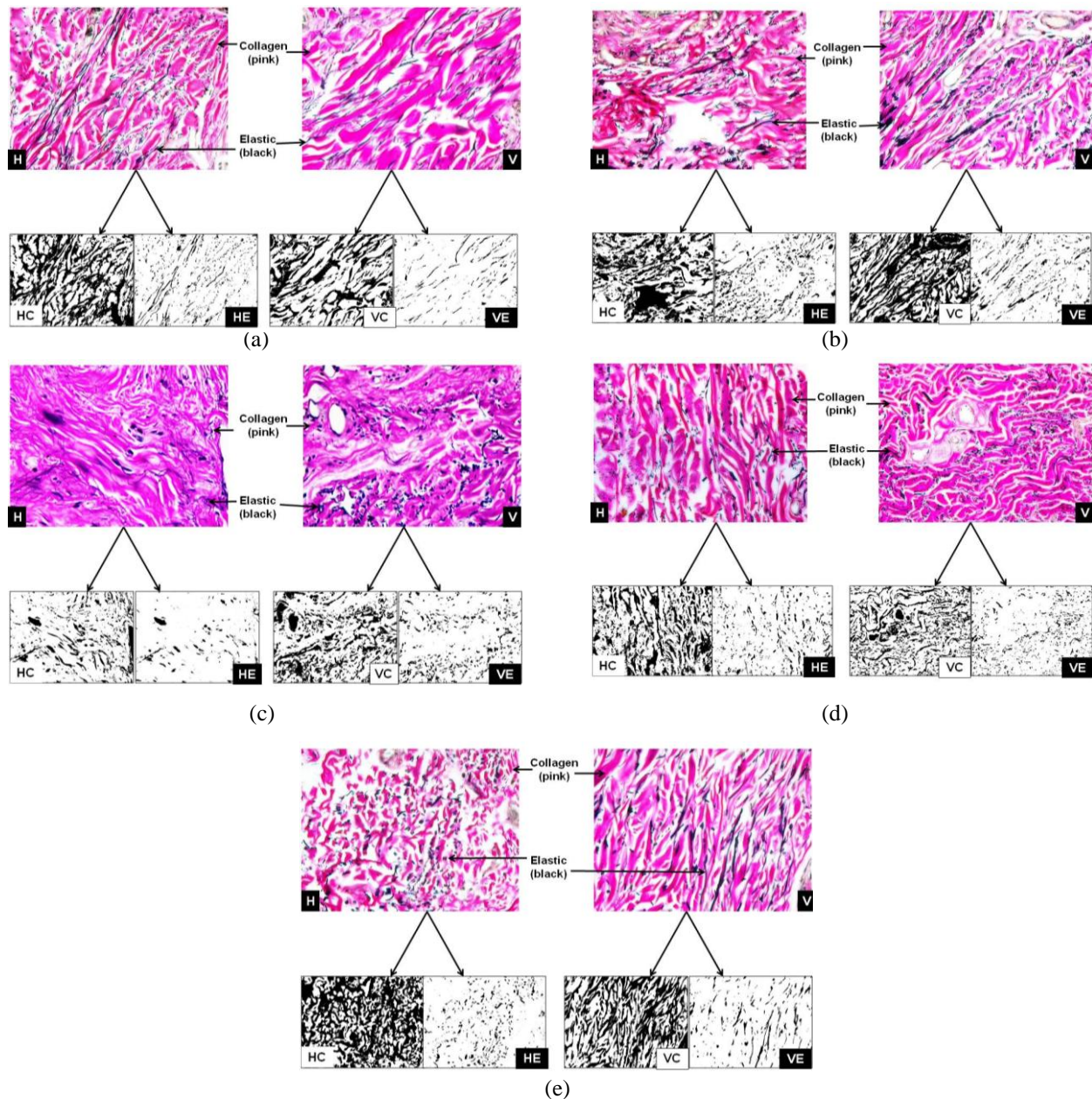


Figure 2: Verhoeff – vanGieson staining appearance of dermal collagen and elastic fibres in horizontal (H) and vertical (V) samples taken from (a) Scalp, (b) Forehead, (c) Lateral canthus, (d) Submandibular region and (e) neck areas of head and neck region (20X magnification). Segmentation of these fibres from the coloured image to black (for elastic) and white (for collagen) shades as for collagen in horizontal (HC) and vertical (VC) as well as elastic in horizontal (HE) and vertical (VE) sections by Tissue –quant software.

Tissue processing

All samples were immersed in 10% formalin before they were processed for the histological slide preparation as per the standard operating procedures. Thin paraffin sections obtained from the microtomy, were stained with special method, Verhoeff-van Gieson (VVG) stain to demonstrate collagen and elastic fibres (6).

Image collection

From the each section stained by VVG method, 3 microphotographs were taken using Progress capture Pro 2.1 – Jenoptic microscopic camera with the resolution of 694x 516 VGA under 20 X magnification. Total of 360 images were collected and they were further subjected to image analysis using ‘Tissue-quant’ software version 1.0 as described below.

Image analysis

Image analysis was done using simple and reliable software call 'Tissue Quant', which is designed with the provision of user interface to select and quantify the colour and its shades of intensity taken up by the target structures. It assigns scores to the choice of colour represented by each pixel of the image, based on closeness of the selected colour (7). The principle of the tissue quant was based on measuring the area occupied by the target structure taken up specific colour and its shades in the image; in the current study it was pink stained collagen and black stained elastic fibres from Verhoeff-van Gieson stain. Prior to analysis, the selected colour and its shades were segmented from the rest of the colours by means of appropriate colour adjustment (Fig. 2a - 2e). The total area occupied by the structures to be analysed were represented by number of pixels are converted to percentage. From the individual results, the average of results obtained from three images was taken for further statistical analysis.

Statistical analysis

Using the percentage values of quantitative fraction of collagen and elastic content, the following parameters were measured by SPSS version 5.

1. Mean with standard error of mean were calculated individually for both directions in each areas of sample obtained. It was calculated separately for collagen and elastic fibres.
2. Paired sample t test was applied to compare all the variables between two different directions. The level of significant were set to be 5% ($p < 0.05$).

Results

Mean (%) values with standard error of means of quantitative fraction between the samples of horizontal and vertical directions from five selected areas of the head and neck region are shown in Table 1 (for collagens) and in Table 2 (for elastic fibres). Results of paired sample t test are also appended in the corresponding table for each area tested.

The result of present study showed the statistical significant difference in quantitative fraction of collagen and elastic fibres between horizontal and vertical directions ($p < 0.01$) in scalp and forehead areas. But in the neck and submandibular region statistically significant difference was observed only for elastic content. On the other hand, in lateral canthal area, though there was a difference in both collagen and elastic fibre content, it was not statistically significant.

Table 1: Results of quantitative fraction analysis (in percentage) of collagen fibres between two directions with their level of significance (p value).

Regions	Horizontal (%Mean \pm SEM)	Vertical (%Mean \pm SEM)	p-value
Scalp	53.5 \pm 1.3	43.8 \pm 2.0	0.001*
Forehead	52.3 \pm 2.8	46.2 \pm 2.5	0.01*
Lateral canthus	44.0 \pm 1.6	40.8 \pm 2.0	0.08
Submandibular region	40.2 \pm 1.6	38.9 \pm 1.4	0.51
Neck	49.4 \pm 2.4	44.6 \pm 2.4	0.07

* indicates statistically significant difference between two directions ($p < 0.01$)

Table 2: Results of quantitative fraction analysis (in percentage) of elastic fibres between two directions with their level of significance (p value).

Regions	Horizontal (%Mean \pm SEM)	Vertical (%Mean \pm SEM)	p-value
Scalp	7.7 \pm 0.5	16 \pm 1	0.001*
Forehead	10 \pm 0.7	7.8 \pm 0.5	0.01*
Lat canthus	12 \pm 1	10.5 \pm 1	0.2
Submandibular region	16 \pm 0.9	23.9 \pm 1	0.001*
Neck	10.5 \pm 0.8	13 \pm 0.7	0.001*

* indicates statistically significant difference between two directions ($p < 0.01$)

Discussion

Dermal collagen exhibits random distribution which enables it for the major role in strength and function. Collagen appears less parallel in deep dermis compared to superficial dermis in the normal skin (8). Microscopic views of normal skin reveal that, the collagen bundles show a basket weave like pattern and appear randomly organised (9). These asymmetries in the arrangement of dermal elements particularly the collagen and elastic fibres mark important clinical complication in the field of aesthetic procedures.

The cleavage lines, also known as Langer's line of skin are formed by definite direction of underlying dermal elements particularly collagen. These lines correspond to the coalition of most of the dermal collagen fibres thus attributing for the flexibility. Understanding the direction of Langer's lines in the specific area of the skin before surgical incision is important for cosmetic value. Thus, a surgical incision made along or parallel to the directions of Langer's lines generally exhibit enhanced healing properties with aesthetic scarring. However, sometimes the exact direction of these lines is unknown because in some regions of the body there are differences among the individuals. And these directional changes of Langer's lines are known to occur in the course of a person's lifetime (10). Probably, this is the one of the cause where in aesthetic surgeons frequently encounter scar related problems in certain areas of the body. This may be due to asymmetrical distribution of collagen and elastic content (5) in addition to their asymmetrical arrangement. Thus, histomorphometric evaluation of dermal connective tissue fibres in different directions perhaps provide valuable guidelines to the aesthetic surgeons in minimising scar related complications and enhance the concept of Langer's line with more supporting basis.

The scar formation and wound contraction results from the full-thickness of skin wounds. Application of native collagen matrices made of native bovine collagen I and elastin in punch biopsy models reduces scar formation and wound contraction (11). In a study comparing type of the collagen present in normal skin with that of usual scar and pathological scars showed a slight increase of type III content in usual scar and significant increase in pathologic scar (12).

A quantitative study on the morphometric analysis of dermal collagen in normal human skin showed significant correlation between the percentage of collagen and its concentration when analysed biochemically. This study also reported the significant correlation between concentration of collagen and age

as implicated by presence of thinner filaments of collagen in reticular dermis of persons aged between 20 to 40 years than older persons (13).

Vitellaro-Zuccarello et al. (14) postulated that, in the reticular dermis there is marked increase in the density of elastic fibres at first decade of life, which eventually drops mainly in males. Aesthetic surgeons supporting this admit that the scar problem is more in children and young age groups (5).

The role of elastic fibres was found to show signs of reduced tensile strength in scar tissue resulted from cutaneous injury due to its reduced amount (15). On other hand, the artificial skin substitute lacking organised elastic fibre arrangement could also result in excessive wound contraction and scarring following post-grafting management (16).

A study conducted by Shuttle-Worth et al. (17) suggests that precursor tropoelastin is present in incisional and excisional wounds. The tropoelastin can be assessed earlier by immune-localisation method than the histological staining method. Authors also inferred that to gain better tissue restoration, manipulation in the elastic fibre synthesis and in its disposition can be carried out in the form of certain skin substitutes. This procedure has been proved by Rnjak et al. (4).

Histomorphometric analysis of present study based on the percentage area occupied by the dermal elements, referred as quantitative fraction can be analysed as follows. The quantitative fraction of collagen is greater in horizontally taken skin samples than its vertical counterparts in all five areas tested from head and neck region. However, this difference in the pattern of distribution between two directions was statistically significant in scalp and forehead areas only. Though the content of elastic fibre is comparatively lower than its collagen complement, its greater allotment was observed in horizontal direction of forehead and lateral canthal areas. But in the scalp, neck and submandibular area it was observed to be higher in vertical section than in horizontal with significant difference.

Two major complications of scar namely hypertrophy due to collagen and stretching due to elastic content are the major challenges for the aesthetic surgeons. These inter-dependent qualities of collagen and elastic fibres establish key role in the consequences of wound healing cascade.

The results of present study showed that where skin are thick and tight (scalp and forehead), the difference

in quantitative fraction of collagen between horizontal and vertical was statistically significant. In other areas (lateral canthus, submandibular area and neck) where skin was relatively thin and loose, the difference was not statistically significant.

Similar to collagen distribution, the quantitative fraction of elastic tissue in two directions was statistically significant where the skin is thick and tight (scalp and forehead). Contrary to collagen tissue, the distribution of elastic tissue in two directions was statistically significant where the skin is relatively thin and less tight (neck and submandibular region). But when the skin is very thin and most mobile (lateral canthus), similar to collagen tissue, the distribution of elastic tissue was also statistically not significant.

Conclusion

This histomorphological evaluation, confirming the asymmetrical content of dermal connective tissue in different orientations in the areas of head and neck region provide possible anatomical basis for explanation to earlier experience that, the scar placed in a particular direction in a given region gives better aesthetic result. This result provides an additional support to the concept of Langer's line in the field of aesthetic surgery which in turn helps the surgeons to improve scar related complications by proper surgical manipulations.

Acknowledgement

To Ms. Mellisa Glenda Lewis (Statistician) for the statistical analysis.

References

1. Lovell CR, Smolenski KA, Duance VC, Light ND, Young S, Dyson M. Type I and III collagen content and fibre distribution in normal human skin during ageing. *Br J Dermatol* 1987; 117(4): 419-428.
2. David EE. *Lever's Histopathology of the skin* 10th (ed). Lippincott Williams & Wilkins. 2008, pp- 7-60.
3. Sherratt JA. Mathematical modelling of scar tissue formation. Department of Mathematics, Heriot-Watt University, Edinburgh. UK. 2010. Available at: <http://www.ma.hw.ac.uk/~jas/researchinterest/scartissueformation.html>. Last accessed on 17/03/2010.
4. Rnjak J, Wise SG, Mithieux SM, Weiss AS. Severe burn injuries and the role of elastin in the design of dermal substitutes. *Tissue Eng Part B Rev* 2011; 17(2): 81-91.
5. Naveen K, Pramod K, Keerthana P and Satheesha NB. A histological study on the distribution of dermal collagen and elastic fibres in different regions of the body. *International Journal of Medicine and Medical Sciences* 2012; 4(8): 171-176.
6. Bancroft JD, Gamble M. *Theory and practice of histological techniques* (5th ed). Churchill Livingstone, Edinburgh. 2002, pp- 127-156.
7. Prasad K, P BK, Chakravarthy M, Prabhu G. Applications of 'Tissue Quant'- a colour intensity quantification tool for medical research. *Comput Methods Programs Biomed* 2012; 106(1): 27-36.
8. van Zuijlen PP, Ruurda JJ, van Veen HA, et al. Collagen morphology in human skin and scar tissue: no adaptations in response of mechanical loading at joints. *Burns* 2003; 29(5): 423-431.
9. Linares HA. Pathophysiology of the burn scar. In: *Total Burn Care*. Herndon DN, editor. 1st. (Ed), WB Saunders Company Ltd, London. 1996, pp- 383-397.
10. David B. Langer's lines of the skin. 2008. Available at <http://www.med-ars.it/galleries/langer.htm>.
11. De Vries HJ, Zeegelaar JE, Middelkoop E, et al. Reduced wound contraction and scar formation in punch biopsy wounds. Native collagen dermal substitutes. A clinical study. *Br J Dermatol* 1995; 132(5): 690-697.
12. Weber L, Meigel WN, Spier W. Collagen polymorphism in pathologic human scars. *Arch Dermatol Res* 1978; 261(1): 63-71.
13. Branchet MC, Boisnic S, Frances C, Lesty C, Robert L. Morphometric analysis of dermal collagen fibres in normal human skin as a function of age. *Arch Gerontol Geriatr* 1991; 13(1): 1-14.
14. Vitellaro-Zuccarello L, Cappelletti S, Dal Pozzo Rossi V, Sari-Gorla M. Stereological analysis of collagen and elastic fibres in the

- normal human dermis: variability with age, sex and body region. *Anat Rec* 1994; 238(2): 153-162.
15. Levenson SM, Geever EF, Crowley LV, Oates JF, Berard CW, Rosen H. The healing of rat skin wounds. *Ann Surg* 1965; 161: 293-308.
 16. Compton C, Gill JM, Bradford DA, Regauer S, Gallico GG, O'Connor NE. Skin regenerated from cultured epithelial autografts on full-thickness burn wounds from 6 days to 5 years after grafting. A light, electron microscopic and immunohistochemical study. *Lab Invest* 1989; 60(5): 600-612.
 17. Shuttleworth L, Black RA, Ferguson MWJ, Herrick SE. Deposition of Elastic Fibres in a Murine Cutaneous Wound Healing Model. *European Cells and Materials* 2005; 10(Suppl. 2): 18.