

Case Report

Transcervical Thyroidectomy for Huge Posterior Mediastinal Goitre: A Challenging Case

Khandasamy Y, Nani Harlina ML, Saladina JJ, Rohaizak M

Department of Surgery, Faculty of Medicine, Universiti Kebangsaan Malaysia Medical Centre, Jalan Yaacob Latif, Bandar Tun Razak, 56000 Cheras, Kuala Lumpur, Malaysia.

Abstract

The decision for median sternotomy for retrosternal goiter is complex and proper consensus are lacking. Generally, it is based on clinical, radiological and intraoperative assessment. Among the few known features include primary mediastinal goiter, posterior mediastinal goiter and recurrent retrosternal goiter. We present a patient with posterior mediastinal, secondary goiter that extended until the tracheal bifurcation. The goiter was removed successfully via a low cervical incision and this was achieved by dissecting along the anatomical plane close to the thyroid capsule using blunt dissection with fingers. It is possible for these kinds of high risk retrosternal goitres to be safely removed without the need for thoracotomy when the surgery was performed along the proper plane.

Keywords: Multinodular goiter, retrosternal goiter, thyroidectomy, sternotomy, substernal goitre

Correspondence:

Prof. Dr. Rohaizak Muhammad, Department of Surgery, Faculty of Medicine, Universiti Kebangsaan Malaysia Medical Centre, Jalan Yaacob Latif, Bandar Tun Razak, 56000 Cheras, Kuala Lumpur, Malaysia. Tel: +60391456206 Fax: +60391456684 Email: rohaizak@hotmail.com

Date of submission: 5 Sept, 2014

Date of acceptance: 9 Mar, 2015

Introduction

A retrosternal goitre is defined as goiter that descends below the thoracic inlet, or has 50% of its volume below the thoracic inlet. It is classified as either primary or secondary and anterior or posterior mediastinum based on the location. A retrosternal goiter carries higher risk of malignancy and airway obstruction (1). Because of these reasons, thyroidectomy is strongly recommended in patients with retrosternal goitre who do not have major comorbid illness (1). Technically, cervical approach is preferred as the majority can be delivered without median sternotomy. A combined cervical and thoracotomy may be needed in cases of large, recurrence posterior ipsilateral or contralateral mediastinal goiter (2). We present a patient with large posterior mediastinal, secondary goiter that extended until the tracheal bifurcation which was removed successfully via a low cervical incision.

Case Report

A 56-year-old Kadazan lady was referred from a private hospital for further management of symptomatic retrosternal goiter. The patient initially presented to the private hospital in 2003 with left neck swelling and subsequently underwent a left hemithyroidectomy in the same year. The histopathology report was multinodular goiter. She was asymptomatic after that until in mid 2010 when she developed a right neck swelling with difficulty swallowing. A computed tomography scan of head, neck and thorax (Fig. 1) was done and subsequently referred to our centre. She denied having shortness of breath or any underlying medical illness. On examination, the right thyroid lobe was palpable and clinically benign. No mass felt on the left side and no cervical lymph nodes were palpable. Clinically and biochemically, she was euthyroid. Computed tomography of the neck showed a heterogeneously enlarged posterior mediastinal mass on the left side.

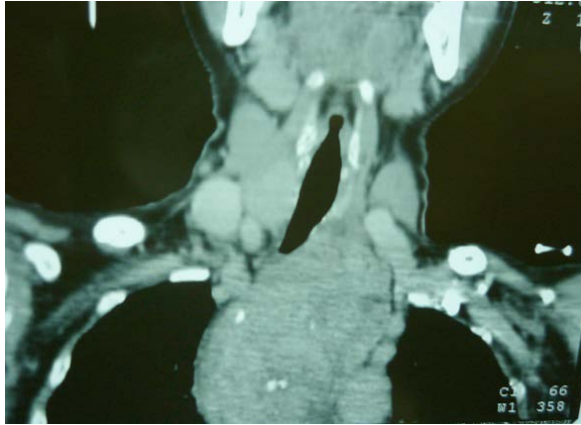

Figure 1: CT scan of the neck showing the left retrosternal extension.

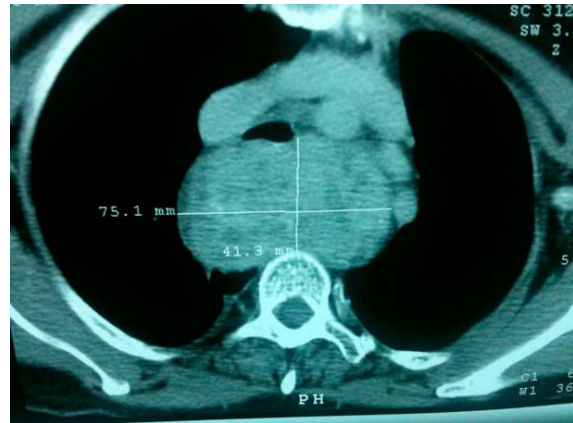

Figure 2: CT scan showing the posterior location of the retrosternal thyroid

The mass extended inferiorly until the level of the carina. The narrowest part of the trachea was 6 mm. There was no encasement of major vessels, trachea or the esophagus (Fig. 2). The patient was positioned on supine position throughout the procedure with the cardiothoracic team on standby. A collar incision for the transcervical approach was used. The strap muscles were divided, followed by the division of the upper pole vessels of right thyroid gland. The right recurrent laryngeal nerve was identified and preserved along with the parathyroid glands. After delivering the right thyroid gland, attention was turned to the retrosternal component. The prevertebral avascular space was created using blunt and sharp dissection. This would facilitate the extraction of the retrosternal goiter from the thoracic inlet. A toboggan manoeuvre where an extracapsular blunt digital dissection of the mediastinal goiter was performed along this prevertebral space, freeing the thyroid from the surrounding structures. A continuous traction was applied to the superior part of the mass coupled with gentle tugging of the gland from side to side facilitates the withdrawal of the gland. The left recurrent laryngeal nerve was adhered to the lateral border of the mass and separated (Fig. 3). The superior part of the gland was not attached to the cervical thyroid at all. The lesion was successfully delivered and weighed 91g. It measured 80 mm x 40 mm x 60 mm. Pleural leak test done prior to wound closure and a size 14 Blake drain was inserted into posterior retrosternal dead space. Her post-operative recovery was complicated when the drain became blocked and caused hematoma with respiratory difficulty about 10 hours post op. The patient was taken to theatre again and evacuation of the haematoma was performed. About 500 ml of blood clots were found in the posterior retrosternal compartment with no obvious source of bleeding. Two 14 F drains were inserted and

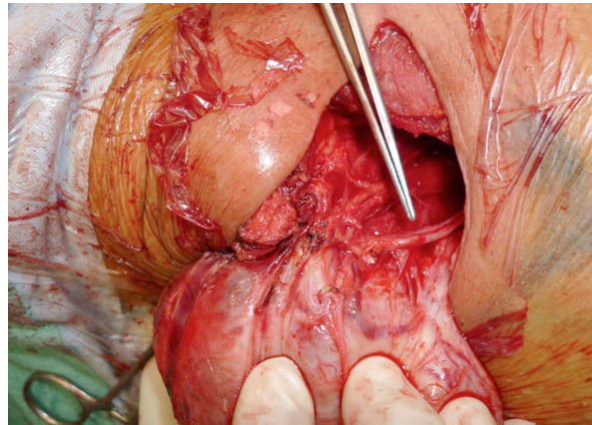


Figure 3: Left recurrent laryngeal nerve adhered and stretched over the lateral border of the retrosternal lesion.

patient was sent to the intensive care unit for monitoring. She recuperated well and discharged on post operative day 5. Pathological assessment of the retrosternal mass confirmed multinodular goiter.

Discussion

A retrosternal goiter usually developed from a slow, progressive growth of the multinodular goiter. It commonly presents itself in the fifth or sixth decade of life (3). The goiter usually follows the normal descent into the mediastinum. A primary mediastinal goiter is a goiter which receives separate blood supply, originating from the mediastinal vessels. This is rarely seen. It accounts for less than 1% of surgically operated patients (4). Isolated posterior retrosternal goitres are extremely very rare. There are only few cases have ever been described in literature (5).

A pre-operative assessment of the anatomical position of the retrosternal goitre is utmost important for the

operative planning. Additional information on the origin of the blood supply will be an advantage to differentiate between primary and secondary goitre. This is best achieved by contrasted computed tomography.

An isolated anterior or posterior primary mediastinal goitre which lies entirely within the thorax is best approached through thoracic approach, either sternotomy or thoracotomy. This is due to the direct blood supply coming from the non-anatomic vessels in the mediastinum, which makes the risk of bleeding higher if approached through the transcervical (2). In contrast, most secondary goitres either anterior or posterior could be removed from a cervical approach as its blood supply and drainage is coming from the inferior thyroid artery and vein respectively, which can be divided at the root of the neck.

In selected cases, a combined approach may be needed especially when dealing with a fixed and adherent posterior mediastinal goitre. This is seen mainly in the reoperative recurrent goitre, goitre that extends beyond the aortic arch and malignancy (6).

With regards to the size of the goitre, Stanislaw et al showed from his recent study that in a subgroup of 35 cases, with the resected tissue weighing more than 300 g and reaching 710 g in one case, had no statistical significance in qualifying patients for sternotomy (7).

The cervical approach was chosen in this patient due to the fact that in this patient, it is a secondary retrosternal goitre originating from the remnant of left thyroid gland which was left behind during the first surgery and appeared as an isolated mass. We anticipated difficulty as the lesion extended until the tracheal bifurcation. By keeping the finger dissection close to the capsule of the lesion, it is safe and possible for the avoidance of an added thoracic approach for these kinds of cases.

Conclusion

It is very important to view each retrosternal goitres individually and with proper clinical and radiological

assessment on the decision for sternotomy. In a high volume centre, it is still possible to attempt transcervical approach for large secondary posterior mediastinal goitres but with a low threshold for a sternotomy or thoracotomy in cases of difficult extraction. Keeping in mind the risk of possible hematoma in the mediastinal dead space and there is a need for proper drainage post operatively.

References

1. Hardy RG, Bliss RD, Lennard TW, Balasubramanian SP, Harrison BJ. Management of retrosternal goitres. *Ann R Coll Surg Engl.* 2009;91(1):8-11
2. Abdullah NH. Multinodular Goitre. In Hubbard JGH et al. (eds.), *Endocrine Surgery, Springer Specialist Surgery Series.* London: Springer; 2009, pp-69-82.
3. Allo MD, Thompson NW. Rationale for the operative management of substernal goiters. *Surgery* 1983; 94(6): 969-77.
4. Gamblin TC, Jennings GR, Christie DB III, Thompson WM Jr, Dalton ML Ectopic thyroid. *Ann Thorac Surg* 2003; 75(6):1952-3.
5. Salomon J, Levy MJ. Mediastinal aberrant goiter; report of two cases. *Dis Chest.* 1967; 52(3): 413-6.
6. Monchik JM, Materazzi G. The necessity for a thoracic approach in thyroid surgery. *Arch Surg.* 2000; 135(4):467-71; discussion 471-2.
7. Cichoń S, Anielski R, Konturek A, Baczyński M, Cichoń W, Orlicki P. Surgical management of mediastinal goiter: risk factors for sternotomy. *Langenbecks Arch Surg.* 2008; 393(5):751-7.