

Pure embryonal carcinoma of testis presenting with extensive metastasis

Sunil Vitthalrao Jagtap¹, Tasneem Vikramsingh Bisht¹, Swati Sunil Jagtap², Anil Huddedar³

¹Department of Pathology, Krishna Institute of Medical Sciences University, Karad, Maharashtra, India.

²Department of Physiology, Krishna Institute of Medical Sciences University, Karad, Maharashtra, India.

³Department of Surgery, Krishna Institute of Medical Sciences University, Karad, Maharashtra, India.

Correspondence to: Sunil Vitthalrao Jagtap, E-mail: drsvjagtap@gmail.com

Received August 1, 2014. Accepted August 14, 2014

Abstract

Embryonal carcinoma is a type of non-seminomatous germ cell tumor. Pure embryonal carcinoma of testis occurs only in 3–4% cases. We present a case of 34-year-old man with aggressive clinical course. At the time of presentation, he had left testicular swelling along with supraclavicular mass with extensive metastasis to retroperitoneum, liver, and lung. On gross pathological examination, specimen showed tumor replacing entire testis with involvement of rete testis, epididymis, and spermatic cord. It is observed that many patients with a tumor composed predominantly of embryonal carcinoma have metastasis at the time of diagnosis. Embryonal carcinoma is an aggressive tumor due to its tendency to early hematogenous spread emphasizing its need for early detection and treatment. The estimation of serum tumor marker levels is not conclusive in these cases. We are presenting this case for its rarity, and advanced stage of disease with clinical and histomorphological features.

KEY WORDS: Embryonal carcinoma, testicular neoplasms, orchidectomy

Introduction

Pure embryonal carcinoma of the testis is relatively rare neoplasm.^[1,2] Embryonal carcinomas are aggressive germ cell tumors due to their tendency to early hematogenous spread. Thus, early detection and management of the patient is important.

Case Report

A 34-year-old man presented in surgery OPD with complaint of pain in left inguinal region for one and half month. There was history of swelling left scrotum that was gradually increasing in size for 8 months. He also gave history of swelling left supraclavicular region for 2 months. There was no gynecomastia. Right-sided testis was normal. There was no history of tuberculosis, diabetes mellitus, hypertension,

orchitis, hormonal or drug treatment, or any other systemic illness. Family history was noncontributory. Patient married 10 years back having three children.

On local examination, a left scrotal swelling measuring 15 × 10 × 5 cm was noted. On ultrasonography (abdomen and pelvis), liver showed enlargement with multiple scattered small nodular lesions; mild-to-moderate splenomegaly was noted. Multiple retroperitoneal nodular lesions were detected. Enlarged left testis showing large mass of heterogeneous echogenicity was strongly suggestive of malignant testicular neoplasm. Final impression being, left testicular neoplasm with multiple site metastasis.

On radiology, chest X-ray showed two opacities, round to oval, likely to be extraparenchymal in nature, suggestive of metastasis was given. Other hematological investigations were normal. Serum α -fetoprotein level was high.

Clinical diagnosis showed malignant left testicular lesion with hydrocele, with left cervical lymphadenopathy with liver, lung, and retroperitoneal metastasis having stage III disease. Patient managed with left-sided high orchidectomy.

We received left orchidectomy specimen measuring 16 × 9 × 6.5 cm and weighing 250 g. On cutting open scrotal sac appears parchment like, which is separate from the testicular mass. On cut section, left testis showed single large, solid, soft to firm, testicular mass, which is gray tan colored with areas of hemorrhage and necrosis [Figure 1].

On microscopic examination, tumor cells were found to be arranged in solid, tubular, papillary, and syncytial pattern

Access this article online

Website: <http://www.ijmsph.com>

DOI: 10.5455/ijmsph.2015.0108201416

Quick Response Code:



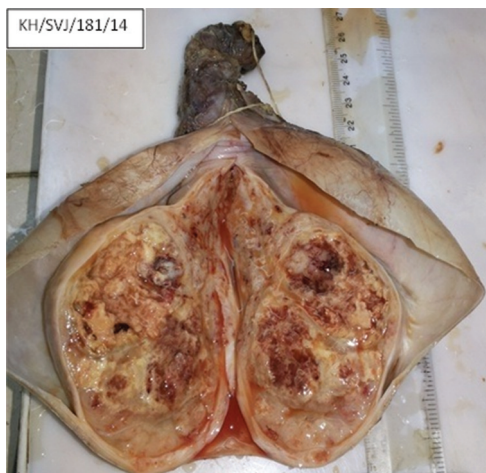

Figure 1: Gross photograph showing left testicular mass. On cut section, showing large, soft to firm, gray tan-colored tumor with areas of hemorrhage and necrosis

[Figure 2]. The cells were large having moderately pleomorphic nuclei and prominent nucleoli. The nuclei showed crowding, overlapping, frequent mitosis. Foci of necrosis were noted. Area of papillary form with fibrovascular core was seen [Figure 3]. Epididymis, spermatic cord [Figure 4], and vascular invasion were noted. Histopathological diagnosis was given as pure embryonal carcinoma of left testis.

Discussion

Although pure embryonal carcinoma is a relatively rare neoplasm, it is the most common component in mixed germ cell tumors.^[3] Pure embryonal carcinoma most commonly occurs at the young age with average age of 32 years.^[2] It is

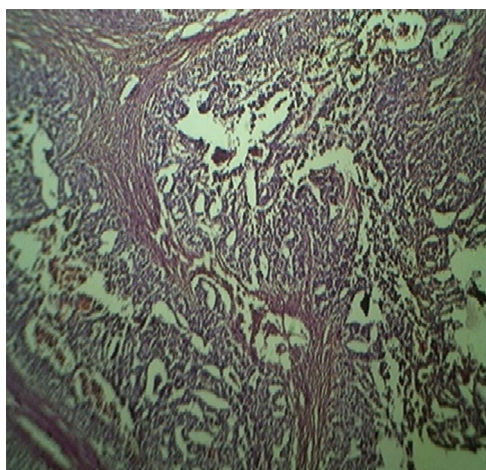


Figure 2: Photomicrograph showing tumor with various histological patterns—solid, tubular, papillary, and syncytial (hematoxylin and eosin stain, 40 ×)

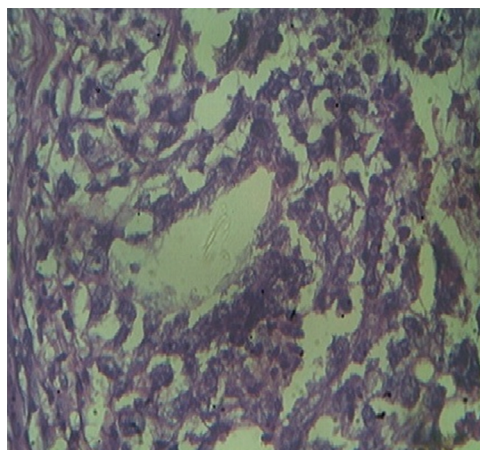


Figure 3: High-power view showing moderately pleomorphic nuclei with prominent nucleoli (hematoxylin and eosin stain, 100 ×)

extremely rare in prepubertal children. Clinically, about 50% patients present with testicular mass without pain, 10% with manifestation of metastasis, and 10% with hormonal symptoms.

In our patient, there was history of pain in scrotal region and swelling, which was neglected by the patient. But when swelling rapidly increased in size in short duration with cervical mass, the patient attended the clinic. At that time, clinical and radiological investigation showed spread and extensive distant metastasis. It has been observed that about 70–80% patients have metastatic disease at the time of diagnosis and 50% of these have distant metastasis.^[4] This indicates the aggressiveness of embryonal carcinoma and its tendency to early hematogenous spread.

On histopathology, about 40% of all testicular germ cell tumors and 90% of mixed germ cell tumors have an embryonal component.^[2] Histologically, tumor cells are arranged in

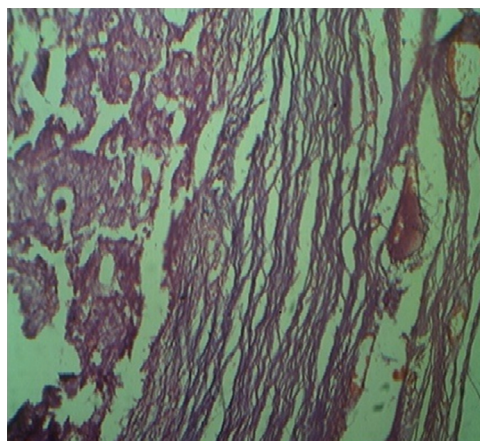


Figure 4: Photomicrograph showing spermatic cord with tumor invasion (hematoxylin and eosin stain, 40 ×)

several architectural patterns and often with more than one pattern. A solid tubular and tubulopapillary pattern are common finding. Along with increased mitotic figures, apoptotic bodies and single cell necrosis are noted. However, there is no prognostic difference associated with the histologic pattern. Cases of pure embryonal carcinoma with focal immature stromal component have been reported. In our case, tumor was arranged in tubular, solid, papillary, and syncytial pattern. Tumor cells were large with pleomorphic nuclei and prominent nucleoli. High mitotic activity, hemorrhage, and necrosis were evident. Vascular and spermatic cord invasion were noted. Other mixed germ cell tumor was not detected on multiple tissue sampling. It is important to distinguish embryonal carcinoma from seminoma, yolk sac tumor, and large-cell lymphoma because of markedly different therapeutic implication. Nowadays, with wide use of testicular ultrasonography, small, non-palpable tumors are being reported more often than in the past.^[5]

Our patient received surgical treatment with left high orchidectomy and chemotherapy. Despite the highly malignant nature of the tumor, the overall 5-year survival rate with treatment used is excellent.^[6]

Conclusion

Pure embryonal carcinoma of testis is a rare tumor. Proper histopathological evaluation, evidence of spread of tumor at the earliest presentation should be carefully looked for, to provide better management and care of the patient.

References

1. Von Hochstetter AR, Hedinger CE. The differential diagnosis of testicular germ cell tumor in theory and practice. A critical analysis of two major system of classification and review of 389 cases. *Virchows Arch A Pathol Anat Histol* 1982;396:247–77.
2. Krag Jacobsen G, Barlebo H, Olsen J, Schultz HP, Starklint H, Søggaard H, et al. Testicular germ cell tumor in Denmark 1976–1980. Pathology of 1058 consecutive cases. *Acta Radiol Oncol* 1984;23:239–47.
3. Bahrami A, Ro JY, Ayala AG. An overview of testicular germ cell tumors. *Arch Pathol Lab Med* 2007;131:1267–80.
4. Vugrin D, Chen A, Feigl P, Laszio J. Embryonal carcinoma of the testis. *Cancer* 1988;61(11):2348–52.
5. Ishida M, Hasegawa M, Kanao K, Oyama M, Nakajima Y. Non-palpable testicular embryonal carcinoma diagnosed by ultrasound: A case report. *Jpn J Clin Oncol* 2009;39(2):124–6.
6. Schmoll HJ, Souchon R, Krege S, Albers P, Beyer J, Kollmannsberger C, et al. European consensus as diagnosis and treatment of germ cell tumor. A report of the European germ cell cancer consensus group (EGCCCG). *Ann Oncol* 2004;15:1377–99.

How to cite this article: Jagtap SV, Bisht TV, Jagtap SS, Huddedar A. Pure embryonal carcinoma of testis presenting with extensive metastasis. *Int J Med Sci Public Health* 2015;4: 145-147

Source of Support: Nil, **Conflict of Interest:** None declared.